

Article XV.—STUDIES IN COMPARATIVE MYOLOGY AND OSTEOLOGY.¹ NO. III

BY W. K. GREGORY AND C. L. CAMP

PLATES XXXIX TO L

CONTENTS

	PAGE
Introduction. By W. K. Gregory.....	447
Part I. A Comparative Review of the Muscles of the Shoulder-girdle and Pelvis of Reptiles and Mammals, with an Attempted Reconstruction of these Parts in <i>Cynognathus</i> , an Extinct Therapsid Reptile. By W. K. Gregory and C. L. Camp.....	450
Part II. A Comparison of the Muscle Areas of the Pelvis of <i>Alligator</i> , <i>Struthio</i> , and <i>Ornitholestes</i> . By W. K. Gregory and C. L. Camp.....	515
Part III. Note on the Origin and Evolution of Certain Adaptations for Forward Locomotion in the Pectoral and Pelvic Girdles of Reptiles and Mammals. By W. K. Gregory.....	515
Part IV. Note on the Morphology and Evolution of the Femoral Trochanters in Reptiles and Mammals, with Special Reference to <i>Cynognathus</i> . By W. K. Gregory.....	528
Part V. A Reconstruction of the Skeleton of <i>Cynognathus</i> . By W. K. Gregory and C. L. Camp.....	538
Part VI. Second Note on the Evolution of the Coracoid Elements in Reptiles and Mammals. By W. K. Gregory.....	545
Summary and Conclusions. By W. K. Gregory.....	553
Explanation of Plates.....	558

INTRODUCTION

BY W. K. GREGORY

The palæontological collections of the world contain great numbers of fossil skeletons which have been described minutely and accurately, but seldom with any detailed reference to the muscles that once moved them. In general, comparative osteology and palæontology are treated in one set of works and comparative myology in another; with few exceptions these

¹ Conducted under the direction of William K. Gregory, Ph.D., Assistant Professor of Vertebrate Palæontology, Columbia University, and Associate in Palæontology, The American Museum of Natural History.

lines of study have been pursued by different workers having little knowledge of each other's results. Only in a very few instances have attempts been made to reconstruct the probable arrangement of the limb muscles in certain extinct animals, as in von Huene's reconstruction of *Plateosaurus* and Lull's reconstruction of *Stegosaurus*, but no wide application of comparative myological results to palæontological material has as yet come to our notice.¹

The objects of the present paper are, first, to make more available to palæontologists the treasures of comparative myology by presenting a convenient introduction to the subject, and, second, to suggest that, when the muscles are taken into consideration, the skeletal elements of both recent and extinct vertebrates acquire a new and manifold interest.

More in detail, the objects of these studies are to review the homologies of similar muscles in the different vertebrate classes; to make restorations of the musculature of the jaws, limbs, and axial skeleton of certain extinct amphibians, reptiles, and mammals; and to discover one by one some of the stages by which the more specialized mechanisms of the higher vertebrates were evolved.

Much has been done by students of comparative myology to make our task practicable. Fürbringer and Gadow especially, in their splendid studies, have collated the literature of the limb muscles of amphibians, reptiles, and birds and clarified the subject greatly by their excellent dissections, critical discussions, and summaries. On the mammalian side, we have used especially the studies of Wilson, McKay, Westling, and Coues on the myology of the monotremes, the "Planches de Myologie" of Cuvier and Laurillard, the accurate text-book of Reighard and Jennings on the cat, Cunningham's "Text-Book of Anatomy," Weisse's "Practical Human Anatomy," and the comparative studies of Windle and Parsons on the myology of the Carnivora and of the Ungulata.² With such data before us, we have attempted a general review and summary of the probable homologies of the pectoral and pelvic muscles in reptiles and mammals, which is a necessary preliminary for our restoration of these parts in *Cynognathus*, as well as for further considerations concerning the evolution of the locomotor organs of vertebrates.

The illustrations for the present paper have been prepared by Mrs. E. M.

¹ Watson's paper (Oct. 1917) on the evolution of the tetrapod shoulder-girdle and fore-limb, which was received too late for extended discussion in this paper, forms an important exception to this statement.

² It is scarcely necessary to add that we have also endeavored, so far as possible, to gain practical knowledge of the subject by dissecting reptiles and mammals for ourselves.

Fulda under the direction of the authors. For the convenience of readers, we have included in our illustrations a selected series of drawings of the musculature of recent reptiles, copied from the works of Fürbringer and Gadow.

Although our observations and conclusions have been frequently revised and reconsidered by us during the last two years, we have no doubt failed to detect all of our own errors in so complex and difficult a subject. Nevertheless, further delay seems inadvisable and we therefore venture to submit our still imperfect results to the critical consideration of anatomists and palæontologists.

The first contribution to these "Studies" was a series of reconstructions of the musculature of the head, vertebral column, and limbs of Eocene and Oligocene titanotheres by W. K. Gregory, assisted by Erwin S. Christman. This will be published in Professor Osborn's monograph on the titanotheres. The second was a memoir on the homologies and functions of the jaw muscles of vertebrates by L. A. Adams, which is now in press (*Ann. N. Y. Acad. Sci.*, 1918). The third is the present paper. The fourth (in progress) is a review of the adaptive radiation of the locomotor apparatus in recent and extinct reptiles, by W. K. Gregory. The fifth (in progress) is a review of the limb muscles of recent amphibians, with an attempted reconstruction of the limbs of *Eryops*, a Permian stegocephalian, by R. W. Miner. The work has been done by, or under the direction of, the senior author of the present paper in the Department of Vertebrate Palæontology of this Museum; it has resulted from the cooperation of the Museum, including members of the staff, with graduate instruction and research in the Department of Zoology, Columbia University. This cooperation was originated by Professor Osborn and President Seth Low in 1891.

To Professors Osborn, Huntington, and Schulte, and to Dr. W. D. Matthew, the authors are indebted both for material and for counsel.

PART I. — A COMPARATIVE REVIEW OF THE MUSCLES OF THE
SHOULDER-GIRDLE AND PELVIS OF REPTILES AND MAMMALS,
WITH AN ATTEMPTED RECONSTRUCTION OF THESE PARTS
IN *CYNOGNATHUS*, AN EXTINCT THERAPSID REPTILE

By W. K. GREGORY AND C. L. CAMP

CONTENTS

	PAGE
Review and Identification of the Muscles of the Shoulder-girdle. By C. L. Camp.....	450
Origins, Insertions and Innervation of Muscles Inserted upon the Scapula and Coracoid in Recent Placentals, Monotremes and Reptiles, with Inferred Conditions in <i>Cynognathus</i>	450
Origins, Insertions and Innervation of Muscles arising on the Scapulo-coracoid and Clavicle in Placentals, Monotremes and Reptiles, with Inferred Conditions in <i>Cynognathus</i>	469
Review and Identification of Muscles Connected with the Pelvis and Sacrum in Placentals, Monotremes, <i>Sphenodon</i> and other Reptiles, with Inferred Conditions in <i>Cynognathus</i> . By W. K. Gregory and C. L. Camp.....	480
Discussion. By W. K. Gregory.....	508

REVIEW AND IDENTIFICATION OF THE MUSCLES OF THE SHOULDER-GIRDLE

By C. L. Camp

Origins, Insertions, and Innervations of Muscles Inserted upon the Scapula and Coracoid in Recent Placentals, Monotremes, and Reptiles, with Inferred Conditions in *Cynognathus*

The muscles running from the neck and flanks to the shoulder-girdle fall into two groups, each group comprising three successive layers, as follows:

I.—Cervical Region

Outermost layer	$\left\{ \begin{array}{l} \text{trapezius} \left\{ \begin{array}{l} \text{clavo-} \\ \text{acromio-} \\ \text{spino-} \end{array} \right. \\ \\ = \text{cucullaris of } Sphenodon \end{array} \right.$
Second layer $\left\{ \begin{array}{l} \text{lateral} \\ \text{dorsal} \end{array} \right.$	$\left\{ \begin{array}{l} \text{omotrachelian} \\ = \text{lev. scap. superf. sup. + inf.} \\ \text{rhomboideus} \end{array} \right.$
Third layer $\left\{ \begin{array}{l} \text{dorsal} \\ \text{and} \\ \text{ventral} \end{array} \right.$	$\left\{ \begin{array}{l} \text{levator scapulæ} \\ (= \text{levator scap. prof.}) \end{array} \right.$

II.—Dorsal Region

Outermost layer	latissimus dorsi
Second layer, lateral	serratus anterior superficialis (serial homologue of omotrachelian)
Third layer, lateral	serratus anterior profundus

In the following pages the names applied to the muscles of placental mammals are set in heavy faced type at the head of each section, followed by the names of muscles in the lower animals which are more or less homologous with them.

Trapezius

CARNIVORA (Windle and Parsons, 1897, p. 385)

Clavo-trapezius

Origin.—Curved line of occiput and ligamentum nuchæ.

Insertion.—Clavicle, on tendinous intersection between this muscle and the deltoid.

Acromio-trapezius

Origin.—Ligamentum nuchæ and spines of anterior thoracic vertebræ.

Insertion.—Anterior border of spine and acromion.

Spino-trapezius

Origin.—Spines of posterior thoracic vertebræ.

Insertion.—Dorsal end of scapular spine.

Innervation.—(Cat) N. accessorius.

MONOTREMES (McKay, 1894, pp. 323–326)

Trapezius anterior (Pls. XLI, *trap.*; XLII)

Origin.—Parietal bone and ligamentum nuchæ.

Insertion (*Ornithorhynchus*).—Anterior extremity of vertebral border of scapula, medial border of spine and acromion, and outer fourth of anterior surface of clavicle.

Trapezius posterior (Pl. XLI, *trap.*)

Origin.—Spines of dorsal vertebræ and dorsal surface of posterior ribs.

Insertion (*Ornithorhynchus*).—Anterior extremity of vertebral border.

Innervation.—N. accessorius.

CYNOGNATHUS (inferred conditions)

Trapezius anterior (Pls. XXXIX, *trap.*; XL, XLI, XLII)

Origin.—As in monotremes.

Insertion.—Spine, acromion and clavicle.¹

¹ Text continued on page 464.

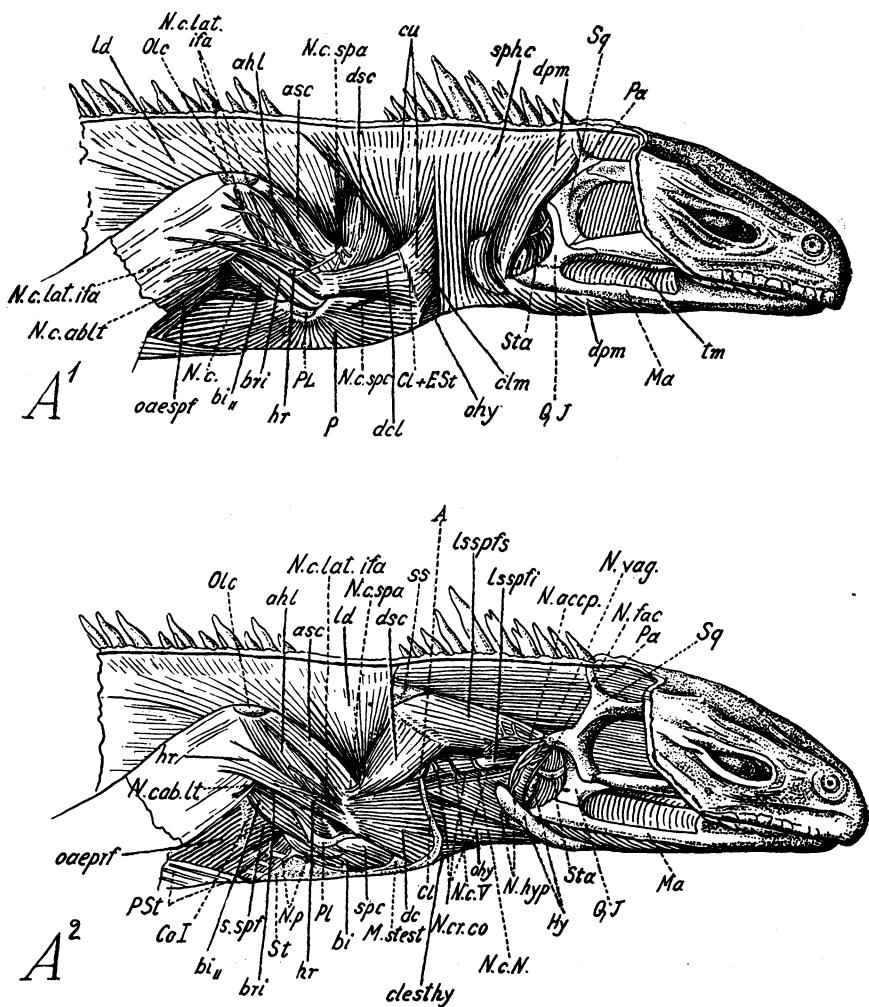


Fig. 1.

Fig. 1. *Sphenodon punctatus*. Pectoral musculature. After Fürbringer 1900.A¹. After removal of the skin.

Abbreviations (Fürbringer)

<i>tm.</i>	temporo-masseter	<i>N. c.</i>	nervous cutaneus
<i>dpm.</i>	depressor mandibulæ	<i>N. c. spa.</i>	nervus cutaneus axillaris supra anconeus
<i>sphe.</i>	sphincter colli	<i>N. c. lat. ifa.</i>	nervus cutaneus brachii et antebrachii superior lateralis infra anconeus
<i>cu.</i>	cucullaris	<i>N. c. ablt.</i>	nervus cutaneus antebrachii lateralis
<i>dsc.</i>	dorsalis scapulæ	<i>N. c. spec.</i>	nervus cutaneus supracoracoideus
<i>ld.</i>	latissimus dorsi	<i>Ma.</i>	malar
<i>asc.</i>	anconeus scapularis	<i>Sta.</i>	stapes
<i>ahl.</i>	anconeus humeralis lateralis	<i>Sq.</i>	squamosal
<i>hr.</i>	humero-radialis	<i>Q. J.</i>	quadrato-jugal
<i>ohy.</i>	omohyoideus	<i>Pa.</i>	parietal
<i>clm.</i>	cleidomastoideus	<i>Cl. + Est.</i>	clavicle + episternum (interclavicle)
<i>dcl.</i>	deltoides clavicularis	<i>PL.</i>	processus lateralis humeri
<i>p.</i>	pectoralis	<i>Olc.</i>	olecranon (patella ulnaris)
<i>oespf.</i>	obliquus abdominis externus superficialis		
<i>bri.</i>	brachialis internus		
<i>bi.</i>	biceps, distal belly		

A². After removal of the sphincter colli, cucullaris, cleidomastoideus and pectoralis.Abbreviations as in A¹, also:

<i>lssps.</i>	levator scapulæ superficialis superior	<i>St.</i>	sternum
<i>SS.</i>	suprascapular	<i>PSI.</i>	parasternum (gastralia)
<i>lsspi.</i>	levator scapulæ superficialis inferior	<i>N. fac.</i>	nervus facialis
<i>dc.</i>	deltoides clavicularis	<i>N. vag.</i>	nervus vagus
<i>clesthy.</i>	cleido episternalis hyoideus	<i>N. accp.</i>	nervus accessorius posterior
<i>spc.</i>	supracoracoideus	<i>N. hyp.</i>	nervus hypoglossus
<i>bi.</i>	biceps, proximal belly	<i>Nc. N.</i>	an error; should be <i>N. c. IV.</i>
<i>sspf.</i>	serratus superficialis	<i>N. c. IV.</i>	nervi cutanei of the thorax
<i>oesprf.</i>	obliquus abdominis externus profundus	<i>N. c. V.</i>	
<i>Hy.</i>	os hyoideum	<i>N. cr. co.</i>	rami musculi cucullaris (from the cervical nerves)
<i>A.</i>	acromion (processus clavicularis)	<i>N. c. spa.</i>	ramus cutaneus nervi supracoracoidei
<i>M.stest.</i>	membrana sterno-episternalis	<i>N. p.</i>	nervus pectoralis
<i>CL.</i>	clavicle		
<i>Co. I.</i>	1st rib (Costa I)		

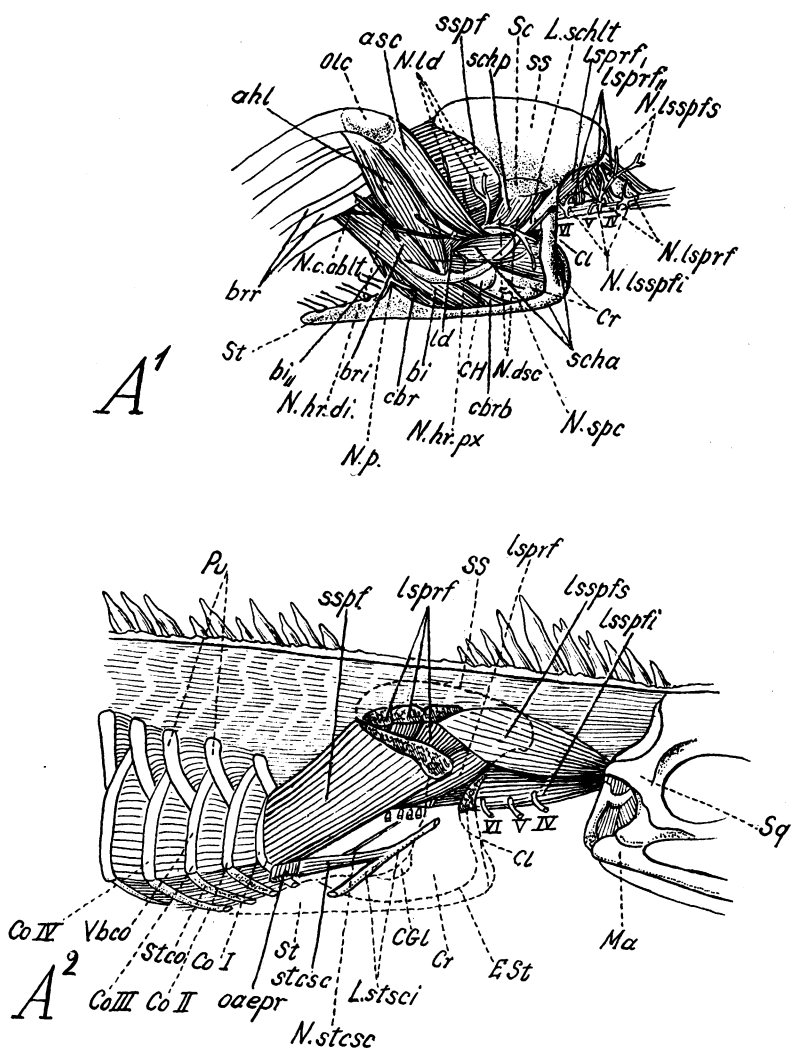


Fig. 2.

Fig. 2. A¹. *Sphenodon punctatus*. Deep muscles of the shoulder-girdle. After Fürbringer 1900.

Abbreviations as in previous figures; also:

<i>lsprf.</i>	levator scapulæ et serratus profundus, superficial layer	<i>IV, V, VI.</i>	spinal nerves
<i>lsprf.</i>	levator scapulæ et serratus profundus, deep layer	<i>N. lsspfs.</i>	nerve for the levator scapulæ superficialis superior
<i>scha.</i>	scapulohumeralis anterior	<i>N. lsspfi.</i>	nerve for the levator scapulæ superficialis inferior
<i>schp.</i>	" posterior	<i>N. lsprf.</i>	nerve for the levator scapulæ et serratus profundus
<i>sspf.</i>	serratus superficialis	<i>N. spc.</i>	nerve for the supracoracoideus
<i>ld.</i>	tendon of latissimus dorsi	<i>N. dsc.</i>	nervus musc. dorsalis scapulæ (N. axillaris posterior)
<i>bi.</i>	biceps (proximal belly)	<i>N. hr. pz.</i>	proximal nerve for the musc. humero-radialis
<i>cbr.</i>	coracobrachialis	<i>N. ld.</i>	nervus musc. latissimi dorsi
<i>cbrb.</i>	coracobrachialis brevis	<i>N. hr. di.</i>	distal nerve for the musc. humero-radialis
<i>brr.</i>	brachio-radialis (M. supinator longus)	<i>N. p.</i>	nervus pectoralis
<i>CH.</i>	caput humeri		
<i>L. schll.</i>	ligamentum scapulohumeralis lateralis		
<i>Cr.</i>	coracoid, with supracoracoid nerve		

A². Deepest muscles of the shoulder. After the removal of the pectoral girdle.

Abbreviations as in preceding figures; also:

<i>stesc.</i>	m. sternocosto-scapularis	<i>Vbco.</i>	vertebro-costale (vertebral part of rib)
<i>oaepr.</i>	obliquus abdominis externus profundus	<i>Sleo.</i>	sternocostale (sternal part of rib)
<i>ESl.</i>	episternum [interclavicle]	<i>Pu.</i>	processus uncinatus
<i>CGL.</i>	glenoid facet of coracoid	<i>IV, V, VI.</i>	spinal nerves
<i>L. stsci.</i>	ligamentum sternoscapularis	<i>N. stesc.</i>	nervus musc. sternocosto-scapularis
<i>Co. I, II, III, IV.</i>	costa I, II, III, IV		

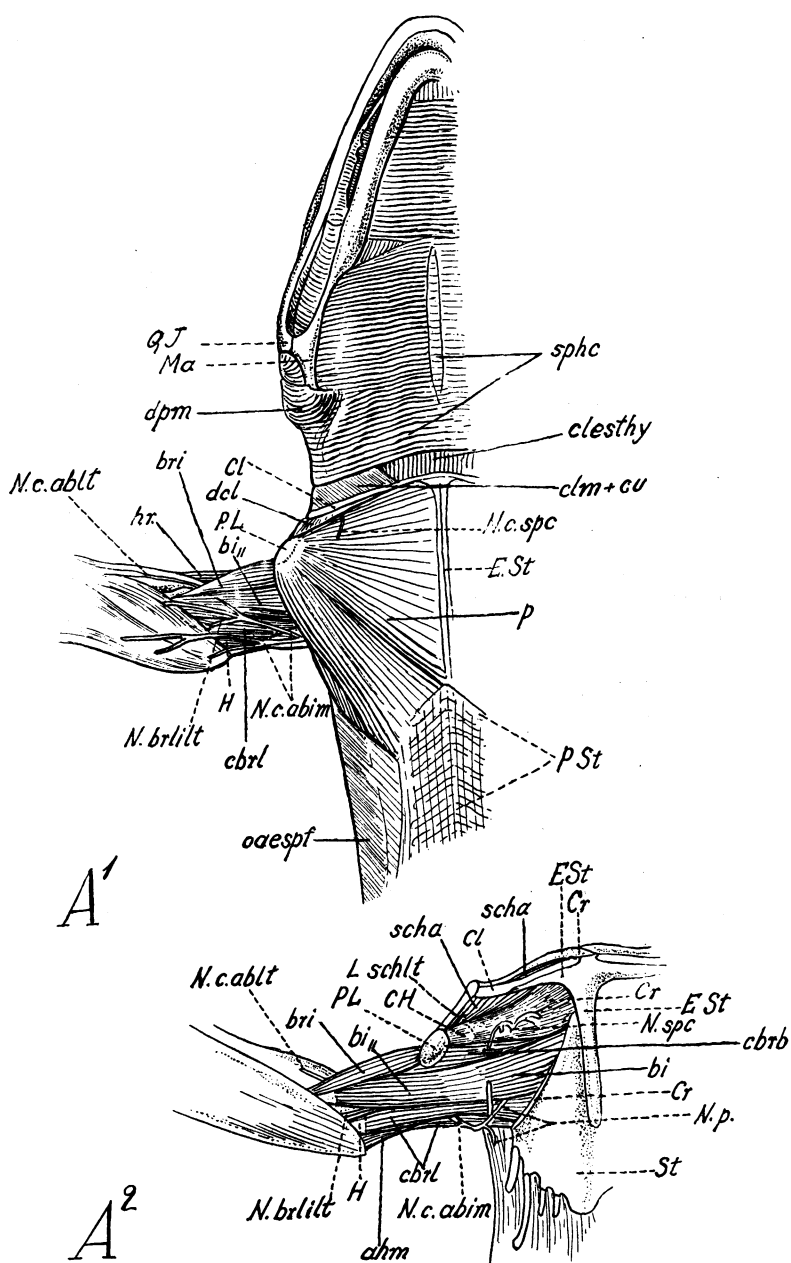


Fig. 3.

Fig. 3. *Sphenodon punctatus*. Pectoral musculature, ventral views. After Fürbringer 1900.

A¹. Superficial muscles.

<i>sphe.</i>	sphincter colli	<i>hr.</i>	humero-radialis
<i>dpm.</i>	depressor mandibulae	<i>cbri.</i>	coracobrachialis longus
<i>clethy.</i>	cleido episternalis hyoideus	<i>H.</i>	humerus
<i>clm. + cu.</i>	cleidomastoideus + cucullaris	<i>N. c. abim.</i>	nervus cutaneus brachii et antebrachii inferior medialis
<i>dcl.</i>	deltoides clavicularis	<i>N. brilt.</i>	nervus brachialis longus inferior lateralis (N. musculo-cutaneus et medianus et profundus)
<i>p.</i>	pectoralis	<i>N. c. abll.</i>	nervus cutaneus antebrachii lateralis
<i>oespf.</i>	obliquus abdominis externus superficialis		
<i>bi.</i>	biceps, distal belly		
<i>bri.</i>	brachialis internus		

A². Deep muscles of the axillary region.

Abbreviations as in preceding figures; also:

<i>N. p.</i>	nervus pectoralis	<i>L. schll.</i>	ligamentum scapulohumeralis lateralis
<i>CH.</i>	caput humeri	<i>ahm.</i>	anconeus humeralis medialis
<i>PL.</i>	processus lateralis humeri		

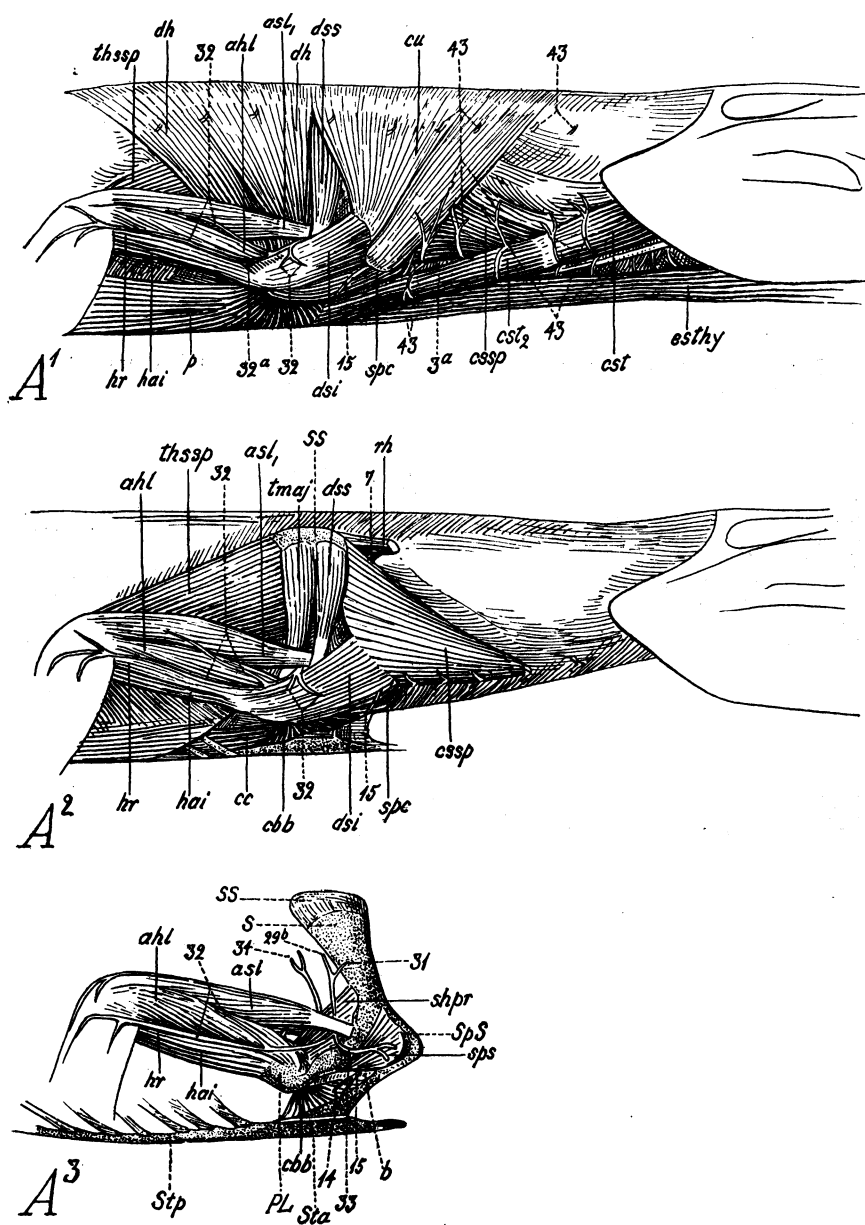


Fig. 4.

Fig. 4. *Crocodylus acutus*. Pectoral musculature. After Fürbringer 1876.

A¹. After the removal of the sphincter colli.

<i>cu.</i>	cucullaris (trapezius)	<i>ahl.</i>	anconeus humeralis lateralis
<i>dss.</i>	dorsalis scapulæ (deltoides scapularis superior)	<i>hai.</i>	humero-antebrachialis inferior (brachialis inferior)
<i>dh.</i>	dorso-humeralis (latissimus dorsi)	<i>hr.</i>	humero-radialis
<i>thssp.</i>	thoraci-scapularis superficialis (serratus superficialis)	<i>p.</i>	pectoralis
<i>esthy.</i>	episterno-hyoideus	<i>43.</i>	cutaneous and muscular branches, arising neither from spinal nerves nor from the plexus brachialis
<i>cst</i> }	capiti-sternalis (sterno-mastoideus)	<i>3a</i>	N. thoracicus anterior (V in <i>Crocodylus</i>)
<i>cst₂</i> }		<i>15.</i>	cutaneous branch of N. supracoracoideus
<i>cssp.</i>	collo-scapularis superficialis (levator scapulæ superficialis)	<i>32</i>	parts of N. axillaris (Nn. cutaneus brachii superior lateralis)
<i>spc.</i>	supracoracoideus	<i>32a</i>	N. humero radialis
<i>dsi.</i>	deltoides scapularis inferior		
<i>asl₁</i>	anconeus scapularis lateralis externus		

A². After the removal of the cucullaris, latissimus dorsi, pectoralis, capiti-sternalis and episterno-hyoideus.

Abbreviations as in A¹; also:

<i>t. maj.</i>	"M. teres major" [of doubtful homology]	<i>ss.</i>	suprascapula
<i>rh.</i>	rhomboideus	<i>7</i>	hinder branch of N. thoracicus superior (VII)
<i>ccb.</i>	coracobrachialis brevis		
<i>cc.</i>	costo coracoideus		

A³. After the removal of the "teres major" (*t. maj.*), deltoides scapularis inferior (*dsi.*), deltoides scapularis superior (*dss.*) and pars coracoidea of the M. supracoracoscapularis (*spc.*).

Abbreviations as in A¹ and A² also:

<i>sps.</i>	pars scapularis of M. supracoracoscapularis	<i>Stp.</i>	posterior part of sternum
<i>b.</i>	biceps, proximal belly	<i>31</i>	N. dorsalis scapulæ (posterior)
<i>shpr.</i>	scapulohumeralis posterior	<i>29b</i>	N. teres major
<i>S.</i>	scapula	<i>34</i>	Nn. latissimi dorsi
<i>SpS.</i>	spina scapulæ	<i>33</i>	branch of N. axillaris for M. deltoides inferior
<i>PL.</i>	processus lateralis humeri	<i>15</i>	cutaneous branch of N. supracoracoideus
<i>Sta.</i>	anterior part of sternum	<i>14</i>	muscular " " " "

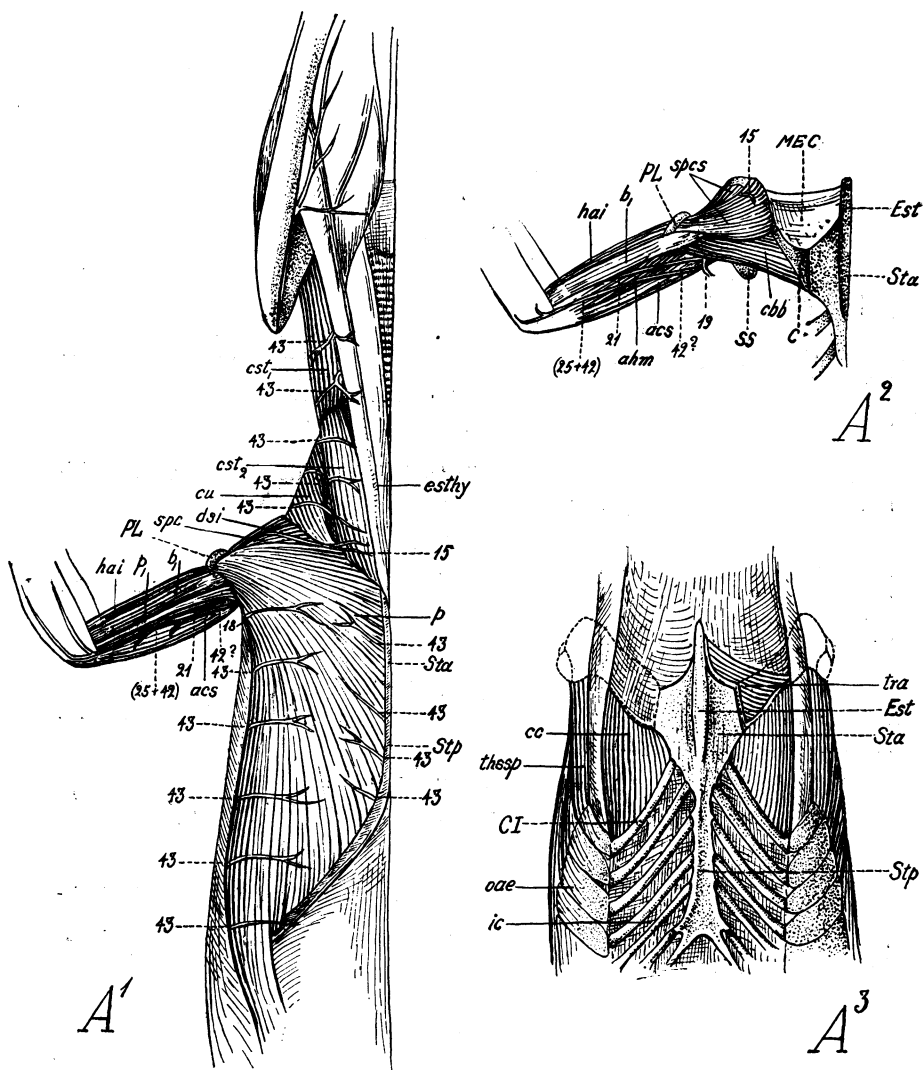


Fig. 5.

Fig. 5. Pectoral musculature of *Crocodilus acutus*. After Fürbringer 1876.

A¹. Ventral view after removal of the skin and of the sphincter colli.

<i>cs₁ cs₂</i>	capiti-sternalis	<i>Sta, Stp.</i>	sternum, anterior and posterior portions
<i>cu.</i>	cucullaris	<i>PL.</i>	processus lateralis humeri
<i>p.</i>	pectoralis, p ₁ separate slip of same	Nerves as in Fig. 4; also:	
<i>dsi.</i>	deltoides scapularis inferior	18	N. cutaneus pectoralis
<i>spc.</i>	supracoracoideus	21	N. brachialis longus inferior
<i>b₁</i>	biceps (distal belly)	(25+42)	N. cutaneus brachii et antebrachii medialis
<i>hai.</i>	humero-antebrachialis inferior (brachialis inferior)	43	(See p. 459)
<i>acs.</i>	anconeus coracoscapularis		

A². Ventral view of the deep muscles of the right shoulder after the removal of the pectoralis, cucullaris, deltoides scapularis inferior.

Abbreviations as in A¹; also:

<i>spcs.</i>	M. supracoracoscapularis	<i>SS.</i>	suprascapula
<i>cbb.</i>	coracobrachialis brevis	19	N. pectoralis
<i>MEC.</i>	membrana episterno-coracoideus	15	cutaneous branch of N. <i>supracoracoideus</i>
<i>C.</i>	coracoid		

A³. Deepest muscles of the pectoral region, ventral view.

<i>tra.</i>	transversus abdominis	<i>ic.</i>	intercostales
<i>cc.</i>	costo coracoideus	<i>Est.</i>	episternum [interclavicle]
<i>thssp.</i>	thoracoscapularis superficialis (serratus anterior superficialis)	<i>Sta., Stp.</i>	sternum, anterior and posterior portions
<i>oae.</i>	obliquus abdominis externus	<i>CI.</i>	costa inferior [gastralium]

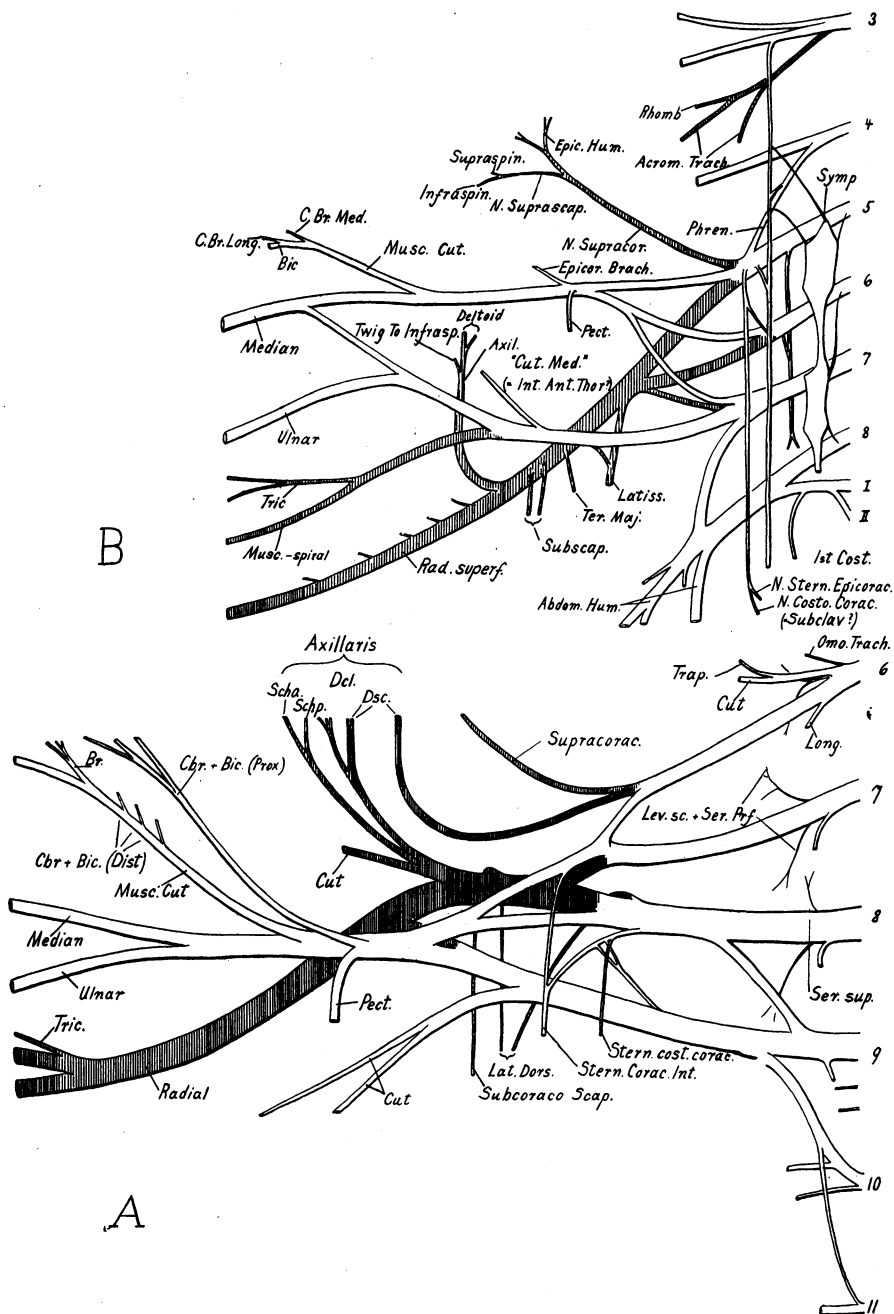


Fig. 6.

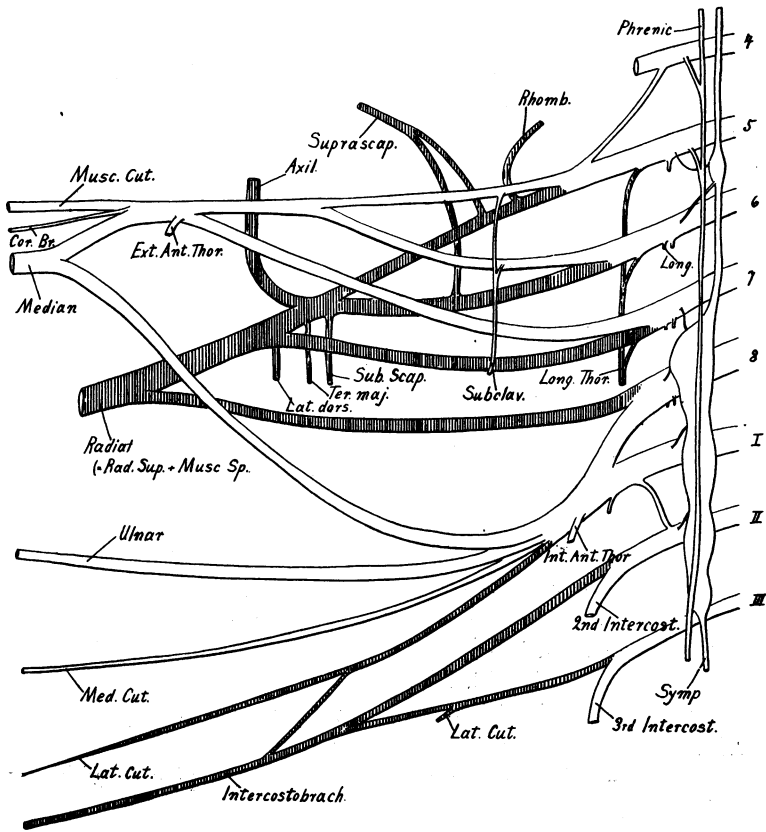


Fig. 7. Brachial plexus of Man. Generalized from Cunningham, 1903, and from Hardesty in Morris and McMurrich. [C. L. C.] Cf. Fig. 6.

Fig. 6. Brachial plexus of (A) *Sphenodon*, generalized from Fürbringer, 1900, and (B) *Ornithorhynchus*, generalized from McKay, 1894. [C. L. C.]

Superior brachial nerves cross hatched; inferior brachial and inferior thoracic nerves white.

Trapezius posterior (Pls. XXXIX, *trap.*; XL, XLI, XLII)

Origin.—As in monotremes.

Insertion.—Spine of scapula.

Remarks.—It seems probable that in *Cynognathus* the eversion of the border of the scapula interrupted the continuous “cucullaris” of *Sphenodon* and caused the primary differentiation of that muscle into acromial and spinous divisions.

SPHENODON (Fürbringer, 1900, pp. 462–464)

Trapezius (capiti-dorso-clavicularis, cucullaris) (Fig. 1, *cu.*)

Origin.—Parietal and squamosal bones.

Insertion.—Lateral two-thirds of clavicle and the “acromion.”

Innervation.—N. accessorius, ramus externus.

Rhomboideus

CARNIVORA (Windle and Parsons, 1897, pp. 386–388)

Rhomboideus anterior

Origin.—Occiput and ligamentum nuchæ.

Rhomboideus posterior

Origin.—Spines of anterior thoracic vertebræ.

Insertion.—Vertebral border of scapula.

Innervation.—(Cat) sixth cervical nerve.

(Man) fourth or fifth cervical nerve.

ORNITHORHYNCHUS (McKay, 1894, p. 336)

Rhomboideus anterior (Pl. XLI, *rhomb.*)

Origin.—Parietal bone and ligamentum nuchæ.

Rhomboideus posterior

Origin.—Ligamentum nuchæ in region of spine of fifth cervical vertebra.

Insertion.—Posterior half of vertebral border.

Innervation.—Third cervical nerve.

CYNOGNATHUS (inferred conditions) (Pls. XXXIX, XL, XLI, XLII)

Origin.—Ligament or fascia above spines of cervical vertebræ.

Insertion.—Anterior vertebral angle of scapula and suprascapula.

CROCODILE (Fürbringer, 1876, pp. 779–780, and 1900, p. 501) (Fig. 4, *rh.*)

Origin.—Fascia above eighth and ninth vertebræ.

Insertion.—Anterior two-thirds of dorsal inner surface of suprascapula.

Innervation.—N. thoracalis superior VII.

Remarks.—According to Fürbringer this muscle (Fig. 4, *rh.*), which

occurs only in the Crocodilia among recent Reptilia, is probably differentiated from the omotrachelian and levator scapulæ complex. Its presence in *Cynognathus* is suggested by the large size of the head and by the presence of an impression, on the anterior corner of the vertebral border of the scapula, which bears marks of a muscle insertion probably distinct from that of the serratus.

SPHENODON

Not present as such.

Omotrachelian

PLACENTALS

(= *Levator scapulæ ventralis*)

Origin.— Transverse process of atlas.

Insertion.— Acromion, near tubercle.

Innervation.— (Cat) third cervical nerve.

(Carnivora, "several cervical nerves" Windle and Parsons).

ORNITHORHYNCHUS (McKay, 1894, pp. 343-344)

Dorsal portion (Pl. XLII, *omotr. dors.*)

Origin.— Distal extremity of external border of hypapophysis of atlas.

Insertion.— Upper part of spine and anterior half of vertebral border of scapula.

Ventral portion (Pl. XLII, *omotr. vent.*)

Origin.— Distal extremity of ventral surface of hypapophysis of atlas.

Insertion.— Ventral two-thirds of spine and adjacent inner surface of scapula, inner border and surface of acromion, and distal part of dorsal face of clavicle.

Innervation.— Third cervical nerve.

CYNOGNATHUS (inferred conditions) (Pls. XXXIX, *omotr.*; XLI, XLII)

Origin.— Transverse process of atlas.

Insertion.— Lateral half of anterior surface of spine ("supraspinous fossa"), antero-dorsal surface of acromion, and outer side of anterior one-third of suprascapula.

SPHENODON (Fürbringer, 1900, pp. 464-466)

Levator scapulæ superficialis superior (Fig. 1, *A*², *lsspfs.*)

Origin.— Transverse processes of first (chiefly) and second cervical vertebræ.

Insertion.—Anterior two-thirds of outer side of suprascapula.

Levator scapulæ superficialis inferior (Fig. 1, *A*², *lsspfi*.)

Origin.—With above.

Insertion.—Anterior border of scapula near "acromion" and dorsal end of clavicle.

Innervation.—Nn. spinales IV, V, and VI.

Remarks.—The levator scapulæ ventralis of placentals may well be homologous with the ventral part of the omotrachelian of monotremes since the origins and insertions are similar in placentals and *Echidna* (see Westling, 1889, p. 13). The origin on the atlantal hypapophysis in *Ornithorhynchus* is doubtless secondary. In *Thylacinus* the muscle is broader than in placentals and has the same insertion as in the latter group.

It appears that the omotrachelian, being a superficial layer, was carried up on the acromion when the latter was everted, leaving the levator ventralis behind to become crowded out upon the advent of the supraspinatus. In *Echidna* the supraspinatus is larger than in *Ornithorhynchus* and the levator ventralis is correspondingly absent.

Levator scapulæ

CARNIVORA (Windle and Parsons, 1897, pp. 388–389)

Levator scapulæ dorsalis (= occipitoscapularis)

Origin.—Posterior tubercles of cervical transverse processes.

Insertion.—Vertebral part of subscapular fossa (with serratus anterior).

Innervation.—(Man) Nn. cervicales III, IV, V.

ORNITHORHYNCHUS (McKay, 1894, pp. 338–339)

Levator scapulæ dorsalis (Pls. XLII, *lev. scap. dors.*)

Origin.—Tips of transverse processes of cervicals 2–7.

Insertion.—Posterior half of inner edge of vertebral border of scapula.

Levator scapulæ ventralis (Pls. XLII, *lev. scap. vent.*)

Origin.—Transverse processes of cervicals 2–6.

Insertion.—Inner half of vertebral border of scapula and whole length of anterior costa and that portion of the supraspinous fossa lying between the insertion of the ventral part of the omotrachelian (ventral portion) and the true anterior costa (median ridge on antero-internal surface).

Innervation.—Nn. cervicales III, IV, V, and VI.

CYNOGNATHUS (inferred conditions) (Pls. XXXIX, *lev. scap.*; XL)

Dorsal portion

Origin.—Transverse processes of cervical vertebræ.

Insertion.—Dorsal edge of inner surface and the whole anterior border of the suprascapula.

Ventral portion

Origin.—Transverse processes of cervical vertebræ.

Insertion.—Median half of anterior border of spine medial to insertion of the omotrachelian, as in monotremes.

SPHENODON (Fürbringer, 1900, pp. 467–468)

Levator scapulæ profundus (Fig. 2, A^1 , A^2 , *lsprf.*)

“Outer” portion

Origin.—Tips of ribs of fifth, sixth, and seventh vertebræ.

Insertion.—Inner surface of cartilaginous suprascapula.

“Inner” portion

Origin.—Transverse processes of third to eighth vertebræ.

Insertion.—Inner surface of cartilaginous suprascapula, dorsal to “outer” portion.

Innervation.—Spinal nerves IV, V, VI, VII, and VIII.

Remarks.—The two divisions of the levator scapulæ profundus of *Sphenodon* probably do not correspond with the two divisions in *Ornithorhynchus*.

In *Cynognathus* the muscle is here placed as in *Ornithorhynchus* because of the presence of the scapular spine and the exclusion of the supraspinatus from its usual position. The ventral portion of the true levator is absent in *Echidna*.

Serratus anterior

CARNIVORA (Windle and Parsons, 1897, pp. 388–389)

Origin.—First to tenth thoracic ribs.

Insertion.—Vertebral part of subscapular fossa (with levator scapulæ dorsalis).

Innervation.—“Posterior thoracic or nerve of Bell.”

ORNITHORHYNCHUS (McKay, 1894, p. 339) (Pl. XLII, *serr. ant.*)

Origin.—First to third dorsal ribs, midway between vertebræ and sternum.

Insertion.—Inside surface of suprascapula and scapula below the insertion of the levator scapulæ dorsalis and above the subscapularis.

Innervation.—(*Ornithorhynchus*) Nn. cervicales III, IV, V, VI.

CYNOGNATHUS (inferred conditions)

Serratus superficialis (Pls. XXXIX, *serr. sup.*; XL, XLI)

Origin.—As in Crocodile.

Insertions.—Flattened posterior border of scapula as far as tubercle for insertion of triceps.

Serratus profundus (Pls. XXXIX, *serr. ant.*; XL, XLI)Origin.—As in *Sphenodon* and perhaps extending further forward.

Insertion.—Inside surface of suprascapula and scapula below the insertion of the dorsal portion of the levator scapulæ and dorsal to the subscapularis.

CROCODILE (Fürbringer, 1876, pp. 776-778; 1900, p. 501)

Serratus superficialis (= thoraci-scapularis superficialis) (Fig. 4, *thssp.*)

Origin.—Last cervical and first three dorsal ribs.

Insertion.—Nearly all of hinder border of scapula.

Innervation.—Nn. thoracici superiores VIII and IX.

Serratus profundus

Origin.—From transverse process of fifth cervical vertebra to first or second rib.

Insertion.—Ventral part of inner surface of suprascapula and adjacent part of scapula.

Innervation.—Nn. thoracici superiores VI-IX.

SPHENODON (Fürbringer, 1900, pp. 466-468)

Serratus superficialis (Fig. 2, *sspf.*)

Origin.—Ribs of eighth and ninth vertebræ.

Insertion.—Postero-ventral moiety of inner border of suprascapula and small adjacent part of scapula.

Innervation.—N. thoracalis superioris (= branch of N. spinalis VIII); also may receive branches from Nn. VII and VIII, or VIII and IX.

Serratus profundus

Upper part

Origin.—Ends of the ribs of fifth, sixth and seventh vertebræ.

Insertion.—Anterior two-thirds of suprascapula, along the middle of the inner face.

Lower part

Origin.—Ribs of last five or six cervical vertebræ.

Insertion.—Five-sixths of the entire width of suprascapula above the insertion of the serratus profundus (upper part) and with the levator scapulæ dorsalis.

Innervation.—N. thoracalis superioris from N. spinales IV or V-VIII.

Omohyoid

CARNIVORA (Windle and Parsons, 1897, pp. 379-380)

Origin.—Hyoid bone.

Insertion.—Anterior border of scapula near suprascapula notch.

Innervation.—(Man) Ansa hypoglossi.

ORNITHORHYNCHUS (McKay, 1894, pp. 345-346) (Pl. XLII, *omohy.*)

Origin.—Basihyal and tendinous intersection of mylo- and stylohyoid.

Insertion.—Inner surface of scapula on a small area between the origin of the supraspinatus and the ventral extremity of the median internal ridge ("true anterior costa").

Innervation.—N. hypoglossus (?).

CYNOGNATHUS (inferred conditions) (Pls. XXXIX, XL, XLII)

Origin.—Hyoid bone.

Insertion.—A facet on dorsal surface of medial acromial ridge, beneath clavicle.

SPHENODON (Osawa, 1898, pp. 525, 540) (Fig. 1, *A², ohy.*)

Origin.—Hyoid bone.

Insertion.—Inner surface of scapula near acromion and on sternoscapular ligament.

Innervation.—N. hypoglossus and N. cervicalis I, ramus ventralis.

Remark.—The omohyoid seems to be strictly homologous in reptiles and mammals.

Origins, Insertions, and Innervations of Muscles Arising on the Scapulo-coracoid and Clavicle in Recent Placentals, Monotremes and Reptiles, with Inferred Conditions in *Cynognathus*

Deltoides

CARNIVORA (Windle and Parsons, 1897, p. 389)

Spino-deltoides

Origin.—Spine of scapula.

Insertion.—Deltoid crest, dorsal to and beneath the acromio-deltoides.

Acromio-deltoides

Origin.—Posterior side of acromion.

Insertion.—Deltoid crest.

Clavo-deltoides

Origin.—Clavicle on clavicular ligament.

Insertion.— Lower half of front face of humerus and sometimes on forearm.

Innervation.— (Cat) N. axillaris.

ORNITHORHYNCHUS (McKay, 1894, pp. 281-282)

Spino-deltoides (= "scapular portion") (Pl. XLI)

Origin.— Anterior two-fifths of external edge of vertebral border of scapula and adjoining external surface; and from upper one-third of outer border of spine.

Insertion.— Tubercle at about mid-point of deltoid crest.

Innervation.— N. axillaris.

Acromio-clavo-deltoides (= "acromio-clavicular part") (Pl. XLI)

Origin.— Ventral surface of transverse portion of interclavicle and the acromion.

Insertion.— Distal three-fourths of deltoid crest and adjoining posterior face of humerus.

Innervation.— N. axillaris and possibly also a minute twig from N. supracoracoideus.

CYNOGNATHUS (inferred conditions)

Probably about as in monotremes (Pls. XXXIX, XL, XLI)

SPHENODON (Fürbringer, 1900, pp. 482-486)

Deltoides scapularis (= spino-deltoid + teres minor = dorsalis scapulæ) (Fig. 1, A², dsc.)

Origin.— Anterior three-fourths and ventral two-thirds of outer face of suprascapula and the adjoining edge of scapula.

Insertion.— Greater tuberosity (processus lateralis, or deltoid crest) of humerus.

Deltoides clavicularis (= clavo + acromio-deltoides = cleido-humeralis) (Fig. 1, A², dc.)

Origin.— Clavicle and interclavicle.

Insertion.— Greater tuberosity (processus lateralis) of humerus.

Innervation.— N. axillaris, ramus cleido-humeralis of ramus dorsalis scapulæ.

Teres minor

CAT (Reighard and Jennings, 1902, p. 161)

Origin.— Glenoid border of scapula.

Insertion.— Greater tuberosity of humerus.

Innervation.— (Man) N. axillaris.

ORNITHORHYNCHUS (McKay, 1894, pp. 316-317) (Pl. XLI.)

Origin.— External face of scapula on ridge extending from dorso-anterior border of glenoid cavity posteriorly and dorsally to the

glenoid crest at the junction of its upper two-thirds with its ventral one-third.

Insertions.—Posterior border of ventral aspect of lesser tuberosity.

Innervation.—A cord formed from fourth, fifth, and sixth cervicals and (in *Echidna*) from the N. axillaris as well.

CYNOGNATHUS (inferred conditions) (Pls. XL, XLI)

Origin.—Possibly from a depression on the posterior surface of the scapula lying between the tuberosity for the tendon of the triceps and the glenoid crest.

Insertions.—Dorsal (posterior) face of humerus lateral to the tuberosity for the insertion of latissimus dorsi and teres major.

SPHENODON

[See under *deltoideus*, above.]

Teres major

CARNIVORA (Windle and Parsons, 1897, pp. 390–391)

Origin.—Dorsal third of axillary border of scapula.

Insertion.—Anterior surface of tendon of M. latissimus dorsi.

Innervation.—(Cat) middle subscapular nerve.

ORNITHORHYNCHUS (McKay, 1894, pp. 314–315) (Pl. XLI)

Origin.—Posterior third of external margin of vertebral border and immediately adjoining face of scapula.

Insertion.—Middle third of inner border of humerus distal to insertion of subscapularis on lesser tuberosity.

Innervation.—Nn. cervicales IV, V, and VI “from which the subscapular nerves also spring.”

CYNOGNATHUS (inferred conditions) (Pls. XXXIX, *ter. maj.*; XL)

Origin.—Dorsal fourth of inner part of axillary border of scapula.

Insertion.—Dorso-posterior surface of humerus on tuberosity for tendon of this muscle and the latissimus dorsi.

SPHENODON

The teres major may be represented either by the anterior part of the latissimus dorsi or possibly by the scapulo-humeralis posterior (see p. 473 below).

Subscapularis

CARNIVORA (Windle and Parsons, 1897, p. 390)

Origin.—Nearly all of internal face of scapula ventral to insertion of serratus anterior and sometimes also from the axillary border.

Insertion.—Lesser tuberosity of humerus.

Innervation.—(Cat) cranial branch of subscapular nerve.

ORNITHORHYNCHUS (McKay, 1894, pp. 314-315) (Pl. XLI)

Origin.— Extensive area on both external and internal faces of scapula.

Insertion.— Distal extremity of lesser tuberosity of humerus.

Innervation.— N. subscapularis from Nn. cervicales IV, V, and VI.

CYNOGNATHUS (inferred conditions) (Pls. XXXIX, XL, XLI, XLII)

Origin.— Nearly entire inner, triangular surface of scapula below insertion of serratus anterior.

Insertion.— Lesser tuberosity (processus medialis).

SPHENODON (Fürbringer, 1900, pp. 489-490)

Pars scapularis of subcoraco-scapularis (= subscapularis).

Origin.— Hinder edge of scapula beneath sterno-scapular ligament.

Insertion.— Lesser tuberosity (processus medialis).

Innervation.— N. subcoraco-scapularis.

Subcoracoideus**PRIMATES** (*Cercopithecus*)

(= coracobrachialis brevis)

Origin.— Ventral surface of coracoid process internal to insertions of biceps brachii and coracobrachialis.

Insertion.— Medial surface of humerus between lesser tuberosity and insertion of teres major. [Occurs in man as a variant.]

Innervation.— (?)

CARNIVORA (Windle and Parsons, 1897, pp. 392-393)

(= rotator humeri, or coracobrachialis brevis)

Origin.— Minute coracoid process.

Insertion.— "Surgical neck" of humerus after "having passed above [over the cephalic border of] the latissimus dorsi."

Innervation.— (?)

ORNITHORHYNCHUS (McKay, 1894, pp. 289-299) (Pl. XLII)

(= epicoraco-brachialis)

Origin.— Outer half of dorsal surface of epicoracoid and adjoining surface of coracoid.

Insertion.— Lesser tuberosity near insertion of subscapularis.

Innervation.— N. musculo-cutaneous and from cord from Nn. cervicales IV, V, and VI.

CYNOGNATHUS (inferred conditions) (Pls. XL, XLI, XLII)

Origin.— Dorsal inner surface of epicoracoid and adjacent surface of scapula.

Insertion.— Lesser tuberosity (processus medialis).

SPHENODON (Fürbringer, 1900, pp. 489-490)

(= pars coracoideus of subcoraco-scapularis)

Origin.—Three-fifths of inner surface of epicoraco-coracoid and scapula.

Insertion.—Lesser tuberosity (processus medialis) with pars scapularis.

Innervation.—N. subcoracoscapularis.

Infraspinatus

CARNIVORA

Origin.—Whole infraspinous fossa except small ventral part of same.

Insertion.—Greater tuberosity of humerus.

Innervation.—N. suprascapularis.

ORNITHORHYNCHUS (McKay, 1894, pp. 305-306) (Pl. XLI)

Origin.—Large part of anterior three-fourths of lateral surface of scapula.

Insertion.—Inner part of ventral surface of greater tuberosity and small area on posterior surface of humerus immediately internal to the proximal end of the delto-pectoral ridge.

Innervation.—Chiefly from the N. suprascapularis and in part from the N. axillaris; (Echidna) same.

CYNOGNATHUS (inferred conditions) (Pls. XXXIX, XL, XLI)

Origin.—Nearly whole of infraspinous fossa.

Insertion.—Greater tuberosity (processus lateralis).

SPHENODON (Fürbringer, 1900, pp. 486-489)

Possibly a part of the epicoraco-humeralis, or possibly represented by the following muscle:

Scapulo-humeralis

Scapulo-humeralis anterior (Fig. 2, A¹, *scha.*)

Origin.—Dorsal, outer border of coracoid and ventral edge of scapula above M. epicoraco-humeralis.

Insertion.—Fossa between deltoid crest and greater tuberosity.

Innervation.—N. scapulo-humeralis, ramus anterior [= branch of N. axillaris].

Scapulo-humeralis posterior (Fig. 2, A¹, *schp.*)

Origin.—Outer surface of anterior three-fourths of ventral half of scapula.

Insertion.—Dorsal surface of humerus near and medial to insertion of scapulo-humeralis anterior.

Innervation.—N. scapulo-humeralis, ramus posterior [= branch of N. axillaris].

Supraspinatus

CARNIVORA

Origin.—Whole of supraspinous fossa except small ventral area.

Insertion.—Greater tuberosity.

Innervation.—N. suprascapularis.

ORNITHORHYNCHUS (McKay, 1897, pp. 308–309) (Pls. XLI, XLII)

Origin.—Internal face of scapula from a depression between acromion and glenoid cavity near sharp antero-ventral border of scapula.

Insertion.—Ventral aspect of inner part of greater tuberosity.

Innervation.—N. supracoracoideus.

CYNOGNATHUS (inferred conditions) (Pls. XXXIX, XL, XLI, XLII)

Origin.—Roughened pit on the ventro-median side of the acromial ridge.

Insertion.—Greater tuberosity and part of fossa distal to latter.

SPHENODON

Absent, or not differentiated, probably part of the epicoraco-humeralis (Pl. XLIX)

Epicoraco-humeralis (= supracoracoideus)

PLACENTALS

Absent.

ORNITHORHYNCHUS (McKay, 1894, pp. 287–288) (Pls. XLI, XLII, XLIX)

Origin.—Nearly entire ventral surface of epicoracoid.

Insertion.—Ventral surface of greater tuberosity.

Innervation.—N. supracoracoideus.

Remarks.—Evidently the suprascapular nerve of placentals is a branch of the supracoracoideus.

CYNOGNATHUS (inferred conditions) (Pls. XXXIX, XL)

Origin.—Ventral surface of epicoracoid and precoracoid surrounding the foramen supracoracoideum.

Insertion.—Greater tuberosity (processus lateralis).

SPHENODON (Fürbringer, 1900, pp. 474–475) (Pl. XLIX)

Supracoracoideus (Fig. 1, *A² spc.*)

Origin.—Anterior half of epicoraco-coracoid.

Insertion.—Greater tuberosity (processus lateralis) and lateral scapulo-humeral ligament.

Innervation.—N. supracoracoideus.

Coracobrachialis**PRIMATES***Coracobrachialis medius*

Origin.— Tip of coracoid process.

Insertion.— Middle of humerus along medial side.

Innervation.— N. musculocutaneus.

Coracobrachialis longus

Origin.— Tip of coracoid process.

Insertion.— Distal third of humerus along medial side. [Occurs in man as a variant.]

Innervation.— (?)

ORNITHORHYNCHUS (McKay, 1894, pp. 298-301)*Coracobrachialis medius* (= "coracobrachialis brevis" of McKay) (Pls. XLII, XLIX)

Origin.— Concave and outer, posterior border of coracoid between glenoid and origin of coracobrachialis longus. Also from ventral face of coracoid.

Insertion.— Antero-lateral face of humerus on distal curved ridge from greater to lesser tuberosity. Insertion bordered internally by the epicoracobrachialis and teres major, externally and distally by the posterior part of the latissimus dorsi.

Innervation.— Division of musculocutaneous nerve.

Coracobrachialis longus (Pls. XLII, XLIX)

Origin.— By tendon with coracoid head of biceps from the external portion of the distal extremity of the coracoid.

Insertion.— Ridge above entepicondylar foramen.

Innervation.— N. musculocutaneus.

CYNOGNATHUS (inferred conditions)*Coracobrachialis medius et longus* (Pls. XLI, XLII)

Origin.— Distal tip of coracoid.

Insertion.— As in *Ornithorhynchus*.

SPHENODON (Fürbringer, 1900, pp. 475-477)*Coracobrachialis medius* (= "brevis" of Fürbringer) (Fig. 3, *A*², *cbrb.*)

Origin.— Outer (ventral surface of posterior half of epicoraco-coracoid.

Insertion.— Concavity of ventral surface of proximal end of humerus between the greater and lesser tuberosities.

Innervation.— Nn. coracobrachialis, rami proximalis et distalis.

Coracobrachialis longus (Fig. 3, *A*¹, *A*², *cbrl.*)

Origin.— Outer surface of posterior tip of epicoraco-coracoid.

Insertion.—Medio-distal surface of humerus just proximal to entepicondylar foramen.

Innervation.—Same as for coracobrachialis medius.

Biceps brachii

PRIMATES

Long head

Origin.—Supraglenoid tuberosity [= "subcoracoid process"].

Short head

Origin.—Tip of coracoid process.

Insertion.—Dorsal half of bicipital tuberosity of radius, with long head.

Innervation.—N. musculocutaneus (two branches).

ORNITHORHYNCHUS (McKay, 1894, pp. 295–297)

Epicoracoid head (Pls. XLI, XLII, XLIX)

Origin.—Small area on posterointernal portion of ventral surface of epicoracoid.

Insertion.—With coracoid head.

Coracoid head (Pls. XLI, XLII, XLIX)

Origin.—External border of distal extremity of coracoid, with coracobrachialis longus.

Insertion.—Middle third of ulna.

Innervation.—N. musculocutaneus from Nn. cervicales IV, V, VI, and VII.

CYNOGNATHUS (inferred conditions) (Pls. XXXIX, XL, XLI, XLII)

Origin.—Ventral surface of coracoid and possibly also in part from the epicoracoid.

Insertion.—As in *Ornithorhynchus*.

SPHENODON (Fürbringer, 1900, pp. 477–479)

Anterior portion (Fig. 1, A^2 , bi ; Fig. 3, A^2 ; Pl. XLIX)

Origin.—Sagittal, middle third of outer surface of coracoid.

Insertion.—Proximal part of radius and ulna.

Posterior portion (Fig. 1, A^2 , bi_1 ; Fig. 3, A^2 ; Pl. XLIX)

Origin.—A fine strip of muscle from the posterior border of the coracoid with the coracobrachialis longus.

Insertion.—With anterior portion.

Innervation.—Nn. bicipitalis proximalis and bicipitalis distalis.

Conditions in *Cynognathus*.

Innervation from	SPHENODON (Fürbringer)	CROCODYLIA (Fürbringer)	CYNONATHUS (inferred)	MONOTREMES (McKay)	PLACENTALS (Windle and Parsons)
<i>N. accessorius</i>	Trapezius	Trapezius	Anterior trapezius Posterior trapezius	Anterior trapezius Posterior trapezius	Cleidomastoideus Sternomastoideus Clavotrapezius Acromiotrapezius Spinotrapezius
<i>N. hypoglossus</i> + <i>N. c. 1</i>	Omohyoideus	Omohyoideus	Omohyoideus	? Omohyoideus <i>N. hypoglossus</i>	Omohyoideus <i>Ansa hypoglossi</i>
<i>Nr. cervicales</i> 4, 5, 6	Levator scapulae superior Levator scapulae inferior	Levator scapulae superficialis	Omotrachelius dorsalis Omotrachelius ventralis	Omotrachelius dorsalis Omotrachelius ventralis <i>N. s</i>	Absent Omotrachelius (= Levator scapulae ventralis) <i>N. s</i> (cat) Levator scapulae dorsalis <i>s to 5 (man)</i>
4 to 8	Levator scapulae profundus	Levator scapulae profundus	Levator scapulae dorsalis Levator scapulae ventralis Rhomboides?	Levator scapulae dorsalis <i>s to 6</i> Levator scapulae ventralis <i>s</i> Rhomboides <i>N. s</i>	Absent Rhomboides 4, 5, or 6

Interruption from	SPHENODON (Fürbringer)	CROCODYLIA (Fürbringer)	CYNONATHUS (inferred)	MONOTREMES (McKay)	PLACENTALS (Windle and Parsons)
<i>N. thorac. ant.</i>	Pectoralis	Pectoralis	Pectoralis	Pectoralis	Pectoralis
<i>N. thoracicus sup.</i> 7+8	Serratus superficialis	Serratus superficialis	Serratus superficialis	Absent	Absent
<i>N. thoracicus sup.</i> to 8 (<i>N. 4</i> or 5 <i>N. n. 7</i> + 8)	Serratus anterior profundus	Serratus anterior profundus	Serratus anterior profundus	<i>N. 3-6</i> Serratus anterior	<i>N. of Bell</i> Serratus anterior
<i>N. suprascapularis</i> (<i>N. supracoracoides</i>)	Epicoraco-humeralis (in part)	Pars coracoidea of supracoracoides	Epicoraco-humeralis	Epicoraco-humeralis <i>N. supracoracoides</i>	Absent
<i>N. suprascapularis</i> (<i>N. supracoracoides</i>)		Pars scapularis of supracoracoides	Supraspinatus	Supraspinatus	<i>N. suprascap.</i> Supraspinatus
<i>N. scap. hum.</i> (<i>N. axil.</i>)	Scapulo-humeralis (ant. + post.)	Scapulo-humeralis	Infraspinatus	<i>N. suprascap.</i> <i>N. axil.</i> Infraspinatus	Infraspinatus

tion from	(Fürbringer)	(Fürbringer)	(inferred)	(McKay)	(Williams and Gregory)
<i>Nn. subscapulares</i>	Subscapularis (pars coracoideus (pars scapularis) Latissimus dorsi	Subscapularis Teres major Latissimus dorsi	Subcoracoideus Subscapularis Teres major Latissimus dorsi	Also from <i>N. musculo-cut.</i> Subcoracoideus (=epicor. brach.) Subscapularis Teres major Latissimus dorsi	<i>Nn. subscap.</i> Subcoracoideus (=coraco-brach. brevis) Subscapularis Teres major Latissimus dorsi
<i>N. axillaris</i>	Scapulo-deltoid Clavo-deltoid	Scapulo-deltoid (= dorsalis scapulæ) Deltoides scapularis inferior	Teres minor Spino-deltoid Clavo-deltoid	<i>N. 4 to 6</i> Teres minor Spino-deltoid Clavo-deltoid	<i>N. axillaris</i> Teres minor Spino-deltoid Acromio-deltoid Clavo-deltoid
<i>N. musculo-cut. (N. cor. brach., N. bicip.)</i>	Biceps brachii Coracobrachialis medius ("brevis" Fürb.) Coracobrachialis longus	Biceps brachii Coracobrachialis	Biceps brachii Coracobrachialis medius Coracobrachialis longus	Biceps brachii Coracobrachialis medius Coracobrachialis longus	Biceps brachii Coracobrachialis medius Coracobrachialis longus
<i>N. radialis</i>	Triceps	Triceps	Triceps	Triceps	Triceps

REVIEW AND IDENTIFICATION OF MUSCLES CONNECTED WITH THE PELVIS
AND SACRUM IN PLACENTALS, MONOTREMES, SPHENODON, AND OTHER
REPTILES, WITH INFERRED CONDITIONS IN CYNOGNATHUS

By W. K. Gregory and C. L. Camp

The following simple classification of these muscles may make it easier to remember the correspondence of reptilian (listed below on the right) to mammalian (on the left) muscles, and may prepare the way for a discussion of the functions of the muscles.

A.—Muscles Chiefly in Front of the Pelvis

Sacrospinalis	Ilio-costalis cervicis
Longissimus dorsi	
Ilio-costalis	
Obliquus abdominis externus	Obliquus abdominis externus
Rectus abdominis	Rectus abdominis
Pyramidalis	Part of abdominal muscles
Quadratus lumborum }	Quadratus lumborum
Psoas minor }	
Iliacus }	Pubi-ischio-femoralis (trochantericus)
Psoas major }	internus
Pectineus }	

B.—Superficial Muscles of the Thigh and Knee

Rectus femoris	Ambiens
Quadriceps femoris	Femoro-tibialis
Sartorius	Ilio-tibialis internus
	(Ilio-tibialis II)
Gluteus maximus }	Extensor ilio-tibialis
Agitator caudæ }	(Ilio-tibialis I)
Biceps }	Ilio-fibularis
Tenuissimus }	
Semitendinosus	Flexor tibialis externus
Semimembranosus	Flexor tibialis internus

C.—Muscles on the Inner Side of the Thigh (Adductors, etc.)

Gracilis	Pubi-ischio-tibialis
Adductor longus }	Pubi-ischio-femoralis
Adductor brevis }	
Adductor magnus }	

Obturator externus	Pubi-ischio-femoralis externus
Quadratus femoris	Pubi-ischio-femoralis posterior
Gemellus inferior (?)	
Obturator internus	

D.—Deep Gluteal and Tail Muscles

Tensor fasciæ femoris	Ilio-femoralis
Gluteus medius	
Gluteus minimus	
Gluteus ventralis	
Gluteus profundus	
Pyriformis	Caudi-ilio-femoralis
Gemellus superior	
Caudi-femoralis	Caudi-femoralis (partim)
Extensor caudæ medialis	Musculus caudæ dorsalis (partim)
Extensor caudæ lateralis	
Abductor caudæ externus	Ilio-caudalis
Ischio-coccygeus	Ischio-caudalis
Levator ani	"Aftermuskeln"
Pubo-rectalis	(Partly derived from ischio-caudalis.
Pubo-coccygeus	Gadow)
Ilio-coccygeus	
Ilio-sacralis	
Flexor caudæ longus	?Caudi-femoralis (partim)

A.—Muscles Chiefly in Front of the Pelvis

Sacrospinalis

CAT (Reighard and Jennings, 1902, pp. 126-128)

Longissimus dorsi

Origin.—Crest and medial surface of ilium, caudal to articular impression, also from deep layer of lumbo-dorsal fascia.

Insertion.—Transverse processes of thoracic vertebræ.

Innervation.—Dorsal rami of thoracic nerves.

Ilio-costalis (lateral part of the sacrospinalis)

Origin.—By many partly separated bundles lying above the ribs, lateral to the longissimus dorsi.

Insertion.—By tendons on the lateral surface of the ribs.

ORNITHORHYNCHUS (Coues, 1870, pp. 133-134)

"*Sacrolumbalis*"

Origin.—Anterior tip of ilium.

Insertion.—Ribs and transverse processes of cervical vertebræ.

CYNOGNATHUS (inferred conditions) (Pl. XLIV)

Origin.— Medial side of dorsal border of ilium and dorsal surfaces of sacral vertebræ.

Insertion.— Dorsal surfaces of transverse processes and ribs, of lumbar and thoracic vertebræ.

SPHENODON (Osawa, 1898, p. 542)*Ilio-costalis cervicis* (Pl. XLIII)

Origin.— Anterior border of ilium and dorsal surface of lumbar, sacral and caudal vertebræ?

Insertion.— Ends of transverse processes and dorsal and outer surfaces of cervical ribs.

Innervation.— R. dorsales of N. spinales.

Obliquus abdominis externus**CAT** (Reighard and Jennings, 1902, pp. 153–154)

Origin.— Posterior nine or ten ribs.

Insertion.— Median raphe and linea alba, tubercle and cranial border of pubis.

Innervation.— R. ventrales of Nn. thoracales posteriores.

ECHIDNA (Mivart, 1866, p. 381)

Origin.— All ribs except first, and the ilium.

Insertion.— Anterior border of symphysis pubis and internal and external margins of the marsupial bone, and margin of pubis just external to base of marsupial bone.

Innervation.— (?)

CYNOGNATHUS (inferred conditions) (Pls. XLIV, XLV)

Origin.— Posterior ribs.

Insertion.— Marsupial bone and pubis nearby.

SPHENODON (Osawa, 1898, pp. 544, 626) (Pl. XLIII)

Origin.— Uncinate processes of ribs.

Insertion.— Anterior surface of M. rectus abdominis, also on tuberculum pubis and ligamentum postischadicum.

Innervation.— Nn. thoracales.

Rectus abdominis**CAT** (Reighard and Jennings, 1902, pp. 155–156)

Origin.— Tuberculum pubis.

Insertion.— First and second costal cartilages and sternum between first and fourth cartilages.

Innervation.— R. ventrales of Nn. thoracales and lumbales I–III.

ECHIDNA (Mivart, 1866, p. 382)

Origin.— Deep surface of marsupial bone near its external margin.

Insertion.— Posterior end of sternum.

Innervation.— (?)

CYNOGNATHUS (inferred condition)

Origin.— Marsupial bone (Pl. XLIV)

Insertion.— Along sternum.

SPHENODON (Osawa, 1898, pp. 547-548, 626) (Pl. XLIII)

Origin.— Tuberculum pubis and ventral surface of pubis and ischium.

Insertion.— Caudal border of sternum.

Innervation.— Nn. intercostales from nervi thoracales.

Pyramidalis

CAT (absent, according to Reighard and Jennings)

UNGULATA (absent, according to Windle and Parsons)

MAN (often absent)

Origin.— Pubic crest in front of rectus abdominis.

Insertion.— Linea alba.

ECHIDNA (Mivart, 1866, p. 382)

Origin.— Whole inner surface of marsupial bone.

Insertion.— Whole length of linea alba.

Innervation.— (?)

CYNOGNATHUS (inferred condition)

Origin.— Marsupial bone.

Insertion.— Linea alba.

SPHENODON (Osawa, 1898; Gadow, 1882, pp. 94, 95).

Not differentiated from rectus abdominis.

Quadratus lumborum

UNGULATA (Windle and Parsons, 1903, p. 289)

Origin.— Ventral surfaces of transverse processes of lumbar vertebræ, and usually into heads of several posterior ribs.

Insertion.— Sacro-iliac joint on tubercle nearby on ilium.

Innervation.— (Reighard and Jennings, 1902, p. 394). Ventral rami of second and third lumbar nerves (cat).

ECHIDNA (Mivart, 1866, p. 390)

Origin.— Ventral surfaces and posterior margins of posterior two ribs, also sides of centra and transverse processes of the three lumbar vertebræ.

Insertion.— Anterior margin of ilium.

Innervation.— (Westling, 1889, p. 52) Plexus lumbalis.

CYNOGNATHUS (inferred conditions) (Pl. XLIV)

Origin.—Ventral surfaces of dorsal vertebræ and posterior ribs.

Insertion.—Sacro-iliac joint.

SPHENODON (Osawa, 1898, p. 548)

Origin.—Anterior borders of transverse processes of sacral vertebræ (metameric) inward and forward.

Insertion.—Anterolateral surfaces of five presacral vertebræ.

Innervation.—(Gadow, 1882, (b), p. 70), N. spinales 19–24 (alligator).

Remarks.—According to Gadow (1882, pp. 71 and 418) the quadratus lumborum of reptiles includes both the quadratus lumborum and the psoas [minor] of man, and is serially homologous on the one hand with the intercostal muscles and on the other hand with the pubischiofemoralis internus (Part III). In the Crocodilia this powerful muscle is attached to the femur, in front of the great trochanter; it draws the femur forward, inward and upward.

Psoas minor

UNGULATA (Windle and Parsons, 1903, p. 289)

Origin.—Iliopectineal eminence.

Insertion.—Centra of last three or four thoracic and several of the lumbar vertebræ.

Innervation.—(Reighard and Jennings, 1902, p. 394). Rami ventrales of Nn. lumbales II et III (cat).

ECHIDNA (Mivart, 1866, pp. 389–390)

Origin.—Iliopectineal eminence posterior to origin of sartorius.

Insertion.—Last three ribs and centra of last three dorsal vertebræ.

Innervation.—(Westling, 1889, p. 52). Plexus lumbalis.

CYNOGNATHUS (inferred condition)

Perhaps not yet differentiated from *quadratus lumborum*.

SPHENODON

Not differentiated from *quadratus lumborum*.

Iliacus

UNGULATA (Windle and Parsons, 1903, p. 289)

Origin.—Iliac fossa, ventral sacrosciatic ligament, and margin of sacrum.

Insertion.—Lesser trochanter.

Innervation.—(Reighard and Jennings, 1902, p. 397). N. femoralis (cat).

ECHIDNA (Mivart, 1866, p. 390)

Origin.—Whole ventral surface of ilium.

Insertion.—Lesser trochanter and ridge running distally therefrom.

Innervation.—(Westling, 1889, p. 53). N. femoralis.

CYNOGNATHUS (inferred condition) (Pl. XLV)

Origin.—Inner surface of pubis and ischium.

Insertion.—Region of lesser trochanter.

SPHENODON (Osawa, 1898, pp. 571–572)

Pubi-ischio-femoralis internus (Partim) (Pls. XLIII, XLV)

Origin.—Inner surfaces of pubis, ischium and membrana obturatoria; over anterior pubi-iliac angle to

Insertion.—Forward medial surface of proximal part of femur.

Innervation.—Nn. iliopectinei from plexus cruralis.

Psoas major

UNGULATA (Windle and Parsons, 1903, p. 289)

Origin.—Transverse processes and sides of centra of all lumbar vertebræ and centra of posterior thoracic vertebræ.

Insertion.—Lesser trochanter.

Innervation.—(Cat) (Reighard and Jennings, 1902, p. 397). Ventral rami of lumbar nerves V and VI (N. femoralis).

ECHIDNA (Mivart, 1866, p. 390)

Origin.—The three lumbar and first three sacral vertebræ.

Insertion.—Lesser trochanter.

Innervation.—(Westling, 1889, p. 53). N. femoralis.

CYNOGNATHUS (inferred condition).

Part of iliacus (Pl. XLV)

SPHENODON

Part of *pubi-ischio-femoralis internus* (Pls. XLIII, XLV)

Pectineus

UNGULATA (Windle and Parsons, 1903, pp. 272–273)

Origin.—Whole iliopectineal line.

Insertion.—Variable, middle third of femur in *Hyrax*.

Innervation.—Femoral or obturator nerve or both.

ECHIDNA (Westling, 1889, p. 34)

Origin.—Iliopectineal eminence.

Insertion.—Border of femur distal to lesser trochanter.

Innervation.—Branch of N. femoralis (to this muscle and the sartorius).

CYNOGNATHUS (inferred condition)

Origin.—Iliopectineal eminence.

Insertion.—Medial side of femur.

SPHENODON

Part of *pubi-ischio-femoralis internus* (Pl. XLIII)

Remarks.—The *pubi-ischio-femoralis internus* of reptiles has much of the position and functions of the *ilio-psoas* + *pectineus* of mammals, except that it extends further caudad on the inner side of the pelvis.

B.—Superficial Muscles of the Thigh and Knee**Rectus femoris**

CAT (Reighard and Jennings, 1902, p. 201)

Origin.—Triangular area on ilium above acetabulum between acetabular and ischial borders.

Insertion.—Outer surface of patella near proximal border of same.

Innervation.—Ventral rami of sixth and seventh lumbar nerves (N. femoralis).

ORNITHORHYNCHUS (Coues, 1868, p. 166)

Origin.—Iliac shaft just above and anterior to acetabulum (Pl. XLV).

Insertion.—Patella, and, by a second division, into head of tibia.

Innervation.—(Westling, 1884, p. 39). N. femoralis.

CYNOGNATHUS (inferred condition) (Pls. XLIV, XLV)

Origin.—Tuberculum pubis.

Insertion.—Head of tibia.

SPHENODON (Osawa, 1898, p. 576, and Gadow, 1882, pp. 375–377) (Pls. XLIII, XLV)

Ambiens = "*pubo-tibialis*"

Origin.—Near base of tuberculum pubis.

Insertion.—With tendon of *femoro-tibialis* on anterior surface of caput tibiae.

Innervation.—R. *pubi-tibialis* of N. femoralis.

Sartorius

ARTIODACTYLA (Windle and Parsons, 1903, p. 275)

Origin.—(Bovidae) from iliac fascia and Poupart's ligament and by another head from pubis just internal to femoral vessels.

Insertion.—Upper part of tibia on fascia of thigh or on tendon of gracilis.

Innervation.—N. femoralis (ant. crural).

ECHIDNA (Westling, 1889, p. 34)

Origin.—Iliopectineal process.

Insertion.—Median side of capsule of knee over tibia and beneath gracilis.

Innervation.—Branch of N. femoralis (to this muscle and the pectineus).

CYNOGNATHUS (inferred condition) (Pl. XLV)

Ilio-tibialis internus

Origin.—Iliopectineal process.

Insertion.—Inside of head of tibia beneath gracilis.

SPHENODON (Gadow, 1882 (b), pp. 408–410, and Osawa, 1898, p. 575)

Pubi-tibialis (posticus) (Pls. XLIII, XLV)

Origin.—Tubercle of pubis.

Insertion.—Latero-proximal (= medio-proximal) prominence of tibia.

Innervation.—R. pubi-tibialis of N. obturatorius and Rr. breves of N. femoralis.

Remarks.—According to Gadow's later view (1891, p. 150) the pubi-tibialis of lizards (and *Sphenodon*) is not homologous with the sartorius of mammals. The latter is innervated by the anterior crural nerve, which also supplies the quadriceps extensor, psoas, iliacus, and pectineus. In the alligator the ilio-tibialis internus (ilio-tibialis II) is likewise innervated by twigs from the anterior crural nerve, which supplies the homologues of the other muscles named above. We, therefore, provisionally adopt the view that the sartorius of mammals has been derived from the ilio-tibialis internus, which may have been present in primitive reptiles.

Gluteus maximus

PERISSODACTYLA (Windle and Parsons, 1903, pp. 264–266)

(= *Ectogluteus*)

Origin.—Spines of sacral and anterior caudal vertebræ and sometimes the iliac crest.

Insertion.—Outer face of femur below greater trochanter.

Innervation (in Artiodactyla).—Inferior gluteal branch of sciatic.

ECHIDNA (Westling, 1889, pp. 30–31)

Origin.—Spines of sacral and anterior caudal vertebræ.

Insertion.—Tibia and fibula near tarsus.

Innervation.—Branch of tibial nerve (n. glut. inf.).

CYNOGNATHUS (inferred condition) (Pls. XLIV, XLV)

Origin.—Spines of posterior sacral and anterior caudal vertebrae and superior iliac crest.

Insertion.—Upper end of femur near great trochanter.

SPHENODON (Osawa, 1898, pp. 569–570) (Pls. XLIII, XLV)*Ilio-tibialis branch of extensor triceps*

Origin.—Lateral surface of ilium, above origin of iliofemoralis.

Insertion.—Anterior surface of head of tibia with femoro-tibialis (= part of quadriceps).

Innervation.—Ramus iliotibialis of N. cruralis and ramus ilio-tibialis of N. peroneus communis.

Femoro-coccygeus (Agitator caudæ)**HYPSPRYMNODON** (Carlson, 1915, p. 20)

Der M. femoro-coccygeus Agitator caudæ, Frets... geht einschichtig von einigen Schwanzwirbeln aus und befestigt sich an dem Trochanter major und dem ersten Drittel des Femur. In Bezug auf die Insertion hat er sich bei *Hypsiprymnodon* proximalwärts gezogen, da er bei *Thylacinus* und *Phalanger* ..., *Trichosurus* und *Æpyprymnus*, *Petrogale* und *Dendrolagus* das distale Ende des Femur erreicht....

ORNITHORHYNCHUS (Cuvier and Laurillard, Planches de Myologie, Pl. 269, fig. 1; Westling, 1889, p. 30).

Origin.—Fascia over sacrum and coccygeal vertebrae.

Insertion.—Outer side of tibia near distal end.

Remarks.—?Part of gluteus maximus of *Ornithorhynchus*.

CYNOGNATHUS (inferred condition)

Probably not yet differentiated from extensor iliotibialis (Part I).

REPTILES

Posterior part of iliotibialis externus.

Biceps femoris (Caput longum)**UNGULATA** (Windle and Parsons, 1903, p. 272)

Origin.—Tuber ischii.

Insertion.—Fascia of upper half or more on outer side of leg, and a fibrous portion to the calcaneal tuberosity.

Innervation.—Cat, man, nerve to the hamstring muscles (a branch of N. ischiadicus).

ECHIDNA (Westling, 1889, p. 36)

Origin.—Tuber ischii.

Insertion.—Fascia on outer surface of tibia from knee to ankle.

Innervation.—N. tibialis.

CYNOGNATHUS (inferred condition) (Pls. XLIV, XLV)

Origin.—Tuber ischii.

Insertion.—Fascia over fibula, to tibia.

SPHENODON (Osawa, 1898, pp. 575–576) (Pls. XLIII, XLV)*Iliofibularis*

Origin.—Lateral surface of ilium behind origin of iliofemoralis.

Insertion.—Lateral surface of proximal second fourth of fibula.

Innervation.—N. iliofibularis of N. peroneus communis.

Tenuissimus (Caput breve bicipitis, bicipiti accessorius)**CAT** (Reighard and Jennings, 1901, p. 195)

Origin.—Tip of transverse process of second caudal vertebra.

Insertion.—With medial surface of biceps.

Innervation.—N. ischiadicus (peroneal branch).

Remarks.—This muscle is usually regarded as the homologue of the short head of the biceps in man and other Primates (Parsons, 1911, p. 59); this has shifted its origin from the caudal vertebræ to the back of the femur, using the agitator caudæ as a muscle slide (Parsons). Keith (1913, p. 440) says that some authors regard it as part of the muscular sheet which forms the peroneal muscles.

CYNOGNATHUS

Occurrence and position problematical.

ALLIGATOR*?Iliofibularis, part II*

Origin.—From lateral crest of ilium, behind extensor ilio-tibialis I.

Insertion.—Antero-superior lateral surface of tibia near peroneus anterior.

Innervation.—Branch from N. ischiadicus.

Remarks.—Gadow (1882, p. 385) notes that in many carnivores (cat, dog, hyæna, coati, etc.) as figured in the "Planches de Myologie" of Cuvier and Laurillard, there is a muscle called the "accessoire coccygien du biceps" [bicipiti accessorius, tenuissimus] which corresponds almost completely to the M. iliofibularis of reptiles.

Semitendinosus**PERISSODACTYLA** (Windle and Parsons, 1903, pp. 271–272)

Origin.—Tuber ischii and ant. caudal vertebræ.

Insertion.—Second quarter of internal surface of shaft of tibia and a small portion to calcaneal tuberosity as a sheath for the tendo achilleis.

Innervation.—(Man) hamstrings branch from N. tibialis.

ECHIDNA (Westling, 1889, pp. 35-36)

Origin.—Tuber ischii, united with semimembranosus.

Insertion.—Dorsal surface of tibia distal to insertion of semimembranosus.

Innervation.—Nn. obturator and ischiadicus.

CYNOGNATHUS (inferred condition) (Pl. XLV)

Origin.—Outer surface of ischium with semimembranosus near tuber ischii.

Insertion.—Lateral surface of proximal end of tibia.

SPHENODON (Osawa, 1898, pp. 563-574) (Pls. XLIII, XLV)

Ischio-tibialis-posticus, lateral portion (Osawa, 1898, pp. 574-575) = flexor tibialis externus (Gadow, 1882, pp. 395-398)

Origin.—Same as medial portion (see below)

Insertion.—Lateral side of proximal end of tibia.

Innervation.—Same as medial portion (see below).

Semimembranosus**PERISSODACTYLA** (Windle and Parsons, 1903, pp. 270-271)

Origin.—Tuber ischii and anterior caudal vertebræ.

Insertion.—Internal lateral ligament.

Innervation.—(Man) hamstrings branch of sciatic.

ECHIDNA (Westling, 1889, pp. 35-36)

Origin.—Tuber ischii.

Insertion.—Head of tibia beneath internal lateral ligament.

Innervation.—Nn. obturatorius and ischiadicus.

CYNOGNATHUS (inferred condition) (Pl. XLV)

Origin.—Tuber ischii.

Insertion.—Medial side of head of tibia.

SPHENODON (Osawa, 1898 (Pls. XLIII, XLV)

"Ischio-tibialis-posticus," medial portion (Osawa, 1898, pp. 574-575) = flexor tibialis internus (Gadow, 1882, pp. 398-402)

Origin.—Outer surface of tuber ischii, fascia of tail and tendon of M. coccygeo-femoralis brevis.

Insertion.—Medial side of proximal end of tibia and tendon from tibia to lateral condyle.

Innervation.—Nn. ischio-tibiales from plexus sacralis.

C.—Muscles on the Inner Side of the Thigh (Adductors, etc.)

Gracilis

UNGULATA (Windle and Parsons, 1903, pp. 274–275)

Origin.—Whole length of symphysis.

Insertion.—Upper part of inner surface of tibia with sartorius and by a fascicle as part of a sheath for enclosure of tendo achillis.

Innervation.—N. obturatorius.

ECHIDNA (Westling, 1889, pp. 34–35)

Origin.—Bases of marsupial bones, pubic symphysis and part of hinder border of pelvis.

Insertion.—Dorsal surface of tibia distal to insertions of semi-membranosus and semitendinosus.

Innervation.—By two branches of N. obturatorius.

CYNOGNATHUS (inferred condition) (Pls. XLIV, XLV)

Origin.—Whole length of ischio-pubic symphysis and posterior end of marsupial bones.

Insertion.—Median side of tibia near its head.

SPHENODON (Osawa, 1898, p. 537) (Pls. XLIII, XLV)

Pubo-ischio-tibialis

Origin.—Ligamentum pubi-ischiadicum and ischio-pubic symphysis.

Insertions.—Medial side of proximal end of tibia.

Innervation.—R. pubi-ischio-tibialis of N. obturatorius.

Adductor longus

CAT (Reighard and Jennings, 1902, pp. 199–200)

Origin.—Medial three-fourths of cranial border of pubis.

Insertion.—Linea aspera along second and third fifths of femur.

Innervation.—N. obturatorius.

ORNITHORHYNCHUS (Coues, 1868, p. 161) (Pl. XLV)

Origin.—Horizontal ramus of pubis near medial line and on the marsupial bone.

Insertion.—Inner condyle of femur.

CYNOGNATHUS (inferred condition) (Pl. XLV)

Origin.—With adductor magnus on median ventral rami of pubis and ischium.

Insertion.—Median surface of shaft of femur.

SPHENODON (Osawa, 1898, pp. 570-571) (Pls. XLIII, XLV)

Pubi-ischio-femoralis.

Origin.—Pubi-ischiadic ligament.

Insertion.—Middle of hinder side of femur.

Innervation.—Ramus ischio-femoralis of N. obturatorius.

Adductor brevis

CAT (part of adductor femoris)

MAN

Origin.—Body of pubis.

Insertion.—Posterior surface of shaft of femur on line leading from lesser trochanter to linea aspera and on upper three-fourths of linea aspera.

Innervation.—N. obturatorius.

ECHIDNA (Westling, 1889, p. 35)

Origin.—Marsupial bone, pubis and ischium dorsal to gracilis and ventral to adductor magnus.

Insertion.—By two heads, one on femur medial to insertion of iliatus and pectineus, the other on the internal condyle. (This muscle may include the adductor longus of Coues.)

Innervation.—N. obturatorius (Westling, 1884, p. 37).

CYNOGNATHUS (inferred condition)

Probably not recognizable as such.

SPHENODON

Part of pubi-ischio-femoralis.

Adductor magnus

UNGULATA

Part of "adductor mass."

CAT (Reighard and Jennings, 1901, pp. 198-199)

Adductor femoris (= magnus + brevis).

Origin.—Rami of pubis and ischium along whole length of symphysis; from ramus of ischium between symphysis and tuberosity and from tendon of origin common to the two gracilis muscles.

Insertion.—Ventral surface of shaft of femur, from greater trochanter to intercondyloid fossa.

Innervation.—Ventral rami of sixth and seventh lumbar nerves (N. obturatorius).

ORNITHORHYNCHUS (Coues, 1870, pp. 160-161) (Pl. XLV)

Origin.—Ischio-pubic ramus in front of origin of semitendinosus.

Insertion.—Posterointernal face of femur along its proximal half.

ECHIDNA (Westling, 1889, p. 35)

Origin.—Posterior border of pelvis and ventral surface of ischium caudal to obturator foramen.

Insertion.—By a small part on dorsal surface of femur and by a larger part on internal condyle and on its crest with adductor brevis.

Innervation.—Obturator and ischiadic nerves.

CYNOGNATHUS (inferred condition) (Pl. XLV)

Origin.—Ventral border of ischium above gracilis and anterior to semitendinosus and semimembranosus.

Insertion.—Median face of middle of shaft of femur.

SPHENODON (Pl. XLIII)

Part of pubi-ischio-femoralis.

Obturator externus

CAT (Reighard and Jennings, 1902, p. 191)

Origin.—Outer margin of thyroid fenestra.

Insertion.—By strong tendon into digital fossa of femur.

Innervation.—N. obturatorius.

ECHIDNA (Westling, 1889)

Origin.—Medial parts of the pubis and ischium and anterior border of the pubis.

Insertion.—By a tendon, which unites with that of the obturator intermedius and is inserted on the femur between the two trochanters.

Innervation.—N. obturatorius.

CYNOGNATHUS (inferred condition) (Pl. XLV)

As in reptiles.

ALLIGATOR (Gadow, 1882, pp. 414–415) (Pl. XLVI)

Pubi-ischio-femoralis externus.

SPHENODON (Pls. XLIII, XLV)

Part of pubi-ischio-femoralis (see p. 492).

Quadratus femoris

CAT (Reighard and Jennings, 1901, p. 191)

Origin.—Lateral surface of ischium near tuberosity.

Insertion.—Distal two-thirds of ventral border of great trochanter and about half adjacent border of lesser trochanter.

Innervation.—(Man) Tibial nerve, branch to quadratus femoris; from lumbar and sacral plexuses through upper part of sciatic nerve (Cunningham 1903, pp. 597, 607 and Fig. 439).

ECHIDNA (Westling, 1889, p. 32)

Origin.—Dorsal border of ischium from acetabulum to origin of biceps, semimembranosus and semitendinosus.

Insertion.—Proximo-lateral part of dorsal surface of femur and on lateral crest distal to greater trochanter lateral to Mm. obturatores.

Innervation.—Branch of N. tibialis.

CYNOGNATHUS (inferred condition) (Pl. XLV)

Origin.—Dorsal border of ischium from acetabulum to spine.

Insertion.—Crest of great trochanter distal to same, and inner (medial) surface of lesser trochanter.

SPHENODON (Osawa, 1901, p. 563) (Pls. XLIII, XLV)

Ischio-trochantericus (= pubi-ischio-femoralis posterior, Gadow, 1882, pp. 416–420)

Origin.—Inner surface of tuber ischii, also from caudal border and a small strip on outer surface of same.

Insertion.—“Trochanter minor” (= trochanter externus).

Innervation.—In the Alligator this muscle is innervated chiefly by a short thick branch from stem *a* (= N. tibialis) of the sacral plexus and by a small twig from the obturator nerve. In *Sphenodon* the muscle is innervated from the sacral plexus (Osawa), as it is also in lizards and *Chelonia* (Gadow).

Gemellus inferior**CAT** (Reighard and Jennings, 1902, p. 190)

Origin.—Dorsal half of whole lateral surface of ischium between the ischial spine and the ischial tuberosity.

Insertion.—Inner surface of tendon of the obturator internus.

Innervation.—(Man) Tibial nerve, branch to quadratus femoris and gemellus inferior (Cunningham, p. 607).

CYNOGNATHUS (inferred condition)

Possibly not differentiated from quadratus femoris.

SPHENODON

Probably not differentiated from pubi-ischio-femoralis posterior.

Obturator internus**CAT** (Reighard and Jennings, 1901, pp. 192–193)

Origin.—Dorsal surface of ramus of ischium along symphysis and on medial border of ischium from symphysis to tuberosity.

Insertion.—By tendon through lesser sciatic notch into trochanteric fossa with gemellus inferior.

Innervation.—(Man) Obturator internus nerve from sacral plexus (Cunningham, 1903, p. 597)

ECHIDNA (Westling)

Absent.

ORNITHORHYNCHUS (Coues, 1870, p. 162)(= *quadratus femoris*?)

Origin.—Concave posterior border of ischio-iliac ramus and posterior surface of ectotrochanter.

Insertion.—Border and posterior surface of ectotrochanter.

CYNOGNATHUS (inferred condition) (Pl. XLV)Part of *quadratus femoris*.**SPHENODON** (Pls. XLIII, XLV)

Part of ischio-trochantericus.

D. Deep Gluteal and Tail Muscles**Tensor fasciæ femoris****UNGULATES** (Windle and Parsons, 1903, p. 266)

Origin.—It rises from the iliac crest, . . . and spreads out into a fan-shaped muscular mass which usually becomes lost in the fascia lata about the middle of the thigh.

Insertion.—Into the fascia lata on the outer side of the thigh.

Innervation.—From the superior gluteal nerve.

Remarks.—The tensor fasciæ femoris, although at first sight belonging to the superficial layer along with the gluteus maximus, is innervated by the same nerve which supplies the deep gluteal muscles, both in man and ungulates.

ORNITHORHYNCHUS (Westling, 1884; Coues, 1871)

This muscle is not recorded.

CYNOGNATHUS (inferred condition)

Origin.—?Antero-superior margin of ilium.

Insertion.—?Fascia covering the femoro-tibialis.

Remark.—Possibly not yet differentiated from the ilio-femoralis.

SPHENODON

?Not differentiated from ilio-femoralis, which, in turn, represents the anterior part of the caudi-ilio-femoralis (Gadow).

Gluteus medius**CARNIVORA** (Windle and Parsons, 1898, pp. 158–159)*Mesogluteus*

Origin.—Gluteal surface of ilium and fascia lata.

Insertion.—Greater trochanter on its outer and posterior surface.

Innervation.—Superior gluteal nerve.

Remark.—Closely associated with the pyriformis in the Carnivora.

ECHIDNA (Westling, 1889, pp. 31-32)

Origin.—Spinous processes of last sacral vertebræ.

Insertion.—Distal edge of greater trochanter and posteriorly along femur.

Innervation.—Branch of peroneal nerve.

CYNOGNATHUS (inferred condition) (Pls. XLIV, XLV)

Origin.—Posterior part of outer surface of ilium, as part of caudilio-femoralis.

Insertion.—On greater trochanter of femur.

SPHENODON (Osawa, 1898, p. 570) (Pls. XLIII, XLV)*Iliofemoralis*

Origin.—Lateral surface of dorsal part of ilium.

Insertion.—Latero-posterior border of proximal part of femur.

Innervation.—R. muscularis brevis from N. femoralis and R. iliofemoralis from N. peroneus.

Gluteus minimus**CARNIVORA** (Windle and Parsons, 1898, p. 158)*Entogluteus*

Origin.—Ventral part of gluteal surface of ilium.

Insertion.—Front and outer side of greater trochanter.

Innervation.—Superior gluteal nerve.

ECHIDNA (Westling, 1899, pp. 31-32)

"Rest of gluteal group"

Origin.—Lumbodorsal fascia, spinous processes of dorsal vertebræ, first sacral vertebræ and ilium.

Insertion.—Great trochanter.

Innervation.—Crural branch of N. ischiadicus.

CYNOGNATHUS (inferred condition) (Pls. XLIV, XLV)

Origin.—Posterior part of outer surface of ilium, as part of caudilio-femoralis.

Insertion.—Great trochanter.

SPHENODON (Pls. XLIII, XLV)

Part of iliofemoralis.

Gluteus ventralis**CARNIVORA** (Windle and Parsons, P. A. S., 1898, p. 158)*Scansorius, capsularis**Gluteus quartus*

Origin.—Ventral border of the ilium, close to the origin of the rectus femoris.

Insertion.— Lower part of the front of the great trochanter.

Remarks.— “This is a differentiation of the ventral fibres of the entogluteus” (idem).

REPTILES

Ilio-femoralis (partim)

The gluteus ventralis of mammals looks like a derivative of the ilio-femoralis of reptiles.

Gluteus profundus

CARNIVORA (Windle and Parsons, 1898, p. 159)

Gluteus quintus

Ilio-capsularis

Origin.— From the ilium just above the acetabulum, and passes over the capsule of the hip-joint.

Insertion.— Upper part of the anterior surface of the shaft of the femur between the origins of the vastus internus and crureus.

REPTILES

Remark.— The gluteus profundus of mammals appears to be derived from the deepest part of the ilio-femoralis of reptiles.

Pyriformis

CAT (Reighard and Jennings, 1901, pp. 188–189)

Origin.— Tips of transverse processes of last two sacral and first caudal vertebræ.

Insertion.— Proximal part of great trochanter caudal to insertion of *gemellus superior*.

Innervation.— (In Man) sacral plexus from first and second sacral nerves, associated with the origin of the peroneal nerve (Cunningham, 1903, p. 607).

HYPSIPRYMNODON (Carlsson, 1915, p. 21)

Remark.— “Der Muskel wird wie gewöhnlich durch seine Lage dorsalwärts vom Stamm des N. ischiadicus und seine Vereinigung mit dem M. gluteus medius charakterisiert.”

ECHIDNA (Westling, 1888, p. 32)

Absent.

ORNITHORHYNCHUS (Coues, 1870, p. 160)

(= “*Quadratus femoris*”)

Origin.— Transverse processes of coccygeal vertebræ.

Insertion.— Middle of back of femur.

CYNOGNATHUS (inferred condition)

Part of "*caudi-ilio-femoralis*."

SPHENODON (Osawa, 1898, pp. 569-570) (Pls. XLIII, XLV)

Part of "*Coccygeo-femoralis brevis*" (= *caudi-ilio-femoralis*, Gadow).

Origin.—Ventral surfaces of transverse processes of six anterior tail vertebræ.

Insertion.—Tendon of *M. ischio-tibialis-posticus*.

Innervation.—Branch of *N. pudendus externus*, and from *N. postsacralis*.

Remarks.—The pyriformis of mammals appears to represent part of the *caudi-ilio-femoralis* of reptiles. In Crocodilia and lizards the *caudi-ilio-femoralis* is innervated chiefly by the first presacral stem (α) which is associated with the origin of the tibial and peroneal nerves; in mammals the nerve that supplies the pyriformis has similar relations.

Gemellus superior

CAT (Reighard and Jennings, 1901, pp. 189, 401)

Origin.—Elongate area on dorsal border of ilium and ischium between posterior inferior iliac spine and spine of ischium.

Insertion.—Triangular area dorsal to tip of great trochanter.

Innervation.—*N. tibialis*.

Remarks.—The position and innervation of this muscle indicate that it has been derived from the *pubi-ischio-femoralis posterior* of reptiles, along with the *obturator internus*.

CYNOGNATHUS (inferred condition)

Not differentiated from *pubi-ischio-femoralis posterior*.

SPHENODON

Probably not differentiated from *pubi-ischio-femoralis posterior* (*ischio-trochantericus*). See p. 494.

Caudi-femoralis ("M. ischio-femoralis Parsons" Carlsson)

CAT (Reighard and Jennings, 1902, p. 195)

Origin.—"By a flat tendon from the transverse processes of the second and third caudal vertebræ. The muscle forms a flat band which passes distad over the pelvis and caudad of the great trochanter. At the middle of the thigh it ends in a very thin tendon. The tendon passes distad along the medial surface of the biceps femoris, pierces the fascia lata near the knee, and passes to its

Insertion.—Into the middle of the lateral border of the patella" (Reighard and Jennings).

HYPSPRYMNODON (Carlsson, 1915, p. 20)

"Entspringt, von dem vorgehenden Muskel [Femoro-coccygeus, Agitator caudæ] bedeckt, tritt schwanzwärts von ihm ein wenig zutage; er wird von dem N. ischiadicus-Stamme überlagert. Er inserirt mehr distalwärts als der M. femoro-coccygeus, indem er sich längs der ersten Hälfte des Femur anheft. . . durch seine Lage in Verhältnis zum N. ischiadicus dokumentiert er sich als ein M. caudo-femoralis."

ECHIDNA (Westling, 1889, p. 33)

Origin.—Spinous process of first caudal; lies ventrad to the two forks of the ischiadic nerve.

Insertion.—Dorsal surface of femur on a prominence near the crest of the trochanter major, distal to the quadratus femurus and to the obturators, proximal to the gluteus medius.

Innervation.—N. tibialis.

CYNOGNATHUS (inferred condition) (Pl. XLIV)

About as in *Sphenodon*.

SPHENODON (Osawa, 1898, pp. 569–570) (Pl. XLIII)

"*Coccygeo-femoralis longus*" (= caudi-femoralis, Gadow)

Origin.—Transverse processes and ventral surfaces of anterior caudal vertebræ.

Insertion.—On and near great trochanter and by a small strand upon capsule of knee, and lateral side of epicondylus ulnaris femoris.

Innervation.—Rr. musculares of N. postsacralis.

Extensor caudæ medialis (T, Fig. 8)**CAT** (Reighard and Jennings, 1902, p. 137)*Levator caudæ internus*

Origin.—"By numerous fleshy bundles from the spinous processes of the sacral and first caudal vertebræ."

Insertion.—The fibres pass caudad and are inserted by tendons into the articular processes and the dorsal surface of the caudal vertebræ.

Innervation.—Rr. dorsales of Nn. spinalis caudæ (R. & J., p. 404).

Remarks.—"This is a continuation caudad of the multifidus spinæ; it lies next to the dorsal median line, the muscles of right and left side touching one another in the middle line" (Reighard and Jennings).

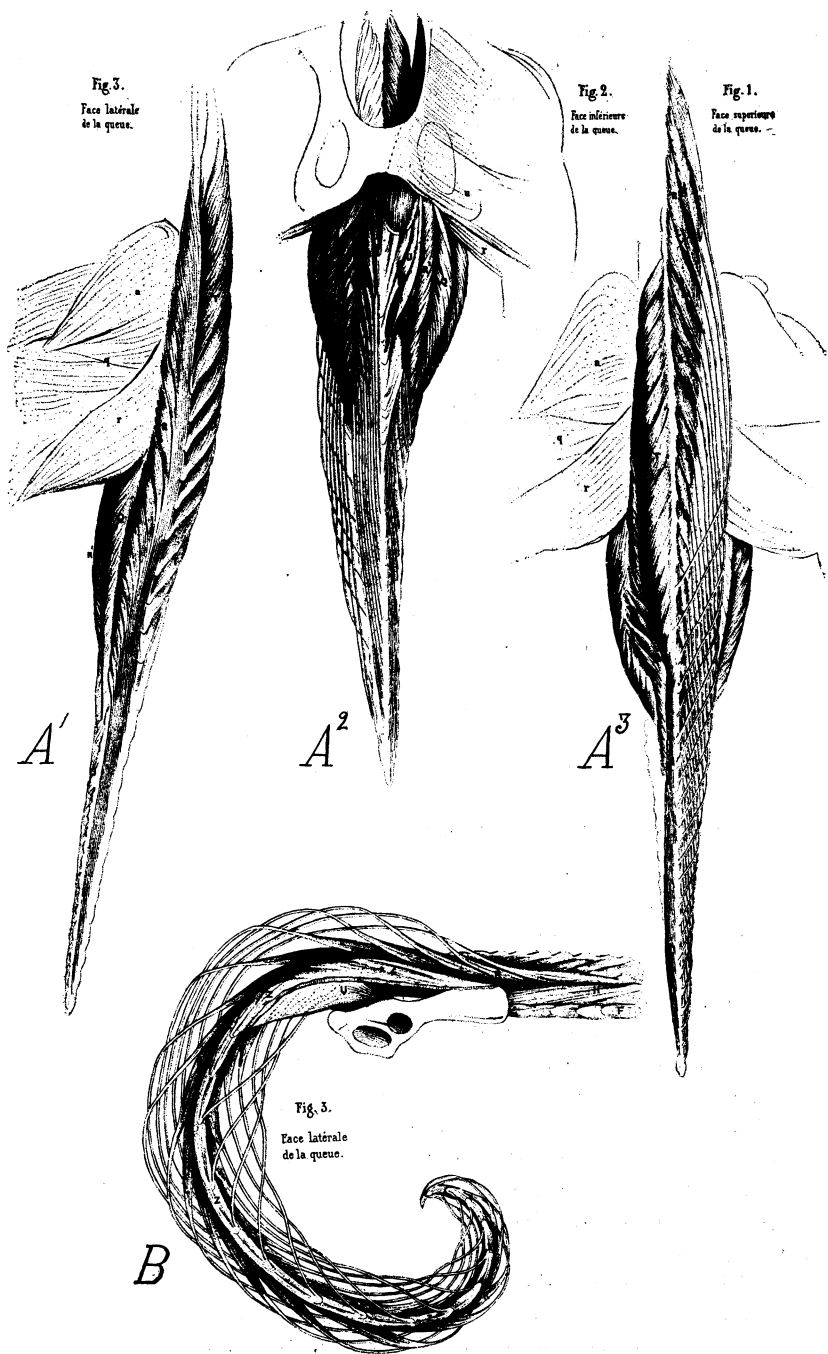
VARIOUS MAMMALS. Cuvier and Laurillard (Planches de Myologie)

T.¹ Interépineux supérieurs.

REPTILES (Gadow)

Musculus caudæ dorsalis (partim).

¹ Symbol used by Cuvier and Laurillard. See Fig. 8.



Extensor caudæ lateralis (R, Fig. 8)

CAT (Reighard and Jennings, 1902, p. 137)

Levator caudæ externus

Origin.—“In many fleshy bundles from the articular processes of the sacral vertebræ, and the transverse processes of the sacral vertebræ, and the transverse processes of the caudal vertebræ.”

Insertion.—“The fibres curve dorsocaudad and are inserted by many long slender tendons on the dorsal surfaces of the caudal vertebræ. The muscle grows continually smaller as it passes caudad” (Idem).

Innervation.—Rr. dorsales of Nn. spinales caudæ (idem, p. 404).

Remarks.—“This is a continuation caudad of the medial portion of the longissimus dorsi; it lies just laterad of the extensor caudæ medialis.” (Idem, p. 137).

VARIOUS MAMMALS

Sacro-coccygeus superior (R). Cuvier and Laurillard (Anat. Comp. Planches de Myologie)

REPTILES

Part of *M. caudæ dorsalis* (Gadow)

Abductor caudæ externus [superior, dorsalis] (Z, Fig. 8)

CAT (Reighard and Jennings, 1902, p. 137)

Intertransversarii caudæ

Origin.—Medial side of dorsal border of ilium and dorsal surface of sacrum.

Insertion.—Transverse processes and lateral surfaces of caudal vertebræ as far back as eighth or ninth.

Innervation.—R. dorsales of N. coccygeus.

ORNITHORHYNCHUS (Coues, 1870, pp. 134–135)

“*Extensor lateralis*” of the tail

Origin.—Posterior edge of ilium.

Insertion.—Tips of transverse processes of caudal vertebræ.

Fig. 8. Tail muscles of mammals. After Cuvier and Laurillard.

A¹ *Castor*, lateral view, left side.

A² The same, ventral view.

A³ The same, dorsal view.

B *Cebus*, lateral view, right side.

Abbreviations (R, etc.) and names of muscles given on page 506.

CYNOGNATHUS (inferred condition) (Pl. XLIV)

Ilio-caudalis

Origin.— Medial side of posterior process of ilium.

Insertion.— Transverse processes of caudal vertebræ.

SPHENODON (Osawa, 1898, pp. 567, 569) (Pl. XLIII)

"Coccygeo-iliacus" (ilio-caudalis, Gadow)

Origin.— Caudal border and inner surface of dorsal end of ilium.

Insertion.— [Transverse processes of caudal vertebræ.]

Innervation.— Rr. dorsales of N. coccygeus.

Ischio-coccygeus (Q, Fig. 8)

CAT (Reighard and Jennings, 1902, p. 137)

Abductor caudæ [inferior]*"Abductor caudæ internus"* (M. coccygeus)

Origin.— Spine of ischium.

Insertion.— Ventral surfaces of transverse processes of second to fourth caudal vertebræ.

ORNITHORHYNCHUS (Coues, 1870, p. 135)

"Flexor lateralis of the tail"

Origin.— Tuber ischii.

Insertion.— Transverse processes of three [anterior?] caudal vertebræ.

CYNOGNATHUS (inferred conditions) (Pl. XLIV)

Ischio-caudalis

Origin.— Spine of ischium.

Insertion.— Ventral side of transverse processes of anterior caudal vertebræ (?).

SPHENODON (Osawa, 1898, pp. 567, 569) (Pl. XLIII)

Coccygeus-ischiadicus (Pars ischio-caudalis des M. ilio-ischio-caudalis Gadow)

Origin.— Tuber ischii.

Insertion.— Ventral sides of transverse processes of caudal vertebræ.

Innervation.— N. coccygeo-ischiadicus, from N. postsacralis II.

Remarks.— The ilio-ischio-caudalis of crocodiles, lizards and *Sphenodon* is a lateral and ventral mass, below the dorsal tail muscles (levators) running from the posterior tip of the ilium and of the ischium. It lies outside of the caudi-femoralis and caudi-ilio-femoralis. The ilio-caudalis, which is still metameric in the alligator, may have given rise to the abductor caudæ externus, or intertransversarii (Z) of mammals; the ischio-caudalis may have given rise to the ischio-coccygeus (Q), ilio-

coccygeus (U) and pubi-coccygeus (X). The caudal part of the caudifemoralis, arising around the chevrons may represent the sacro-coccygeus inferior (R^1) plus interspinalis inferior (V). (See p. 506 and Fig. 8).

Levator ani

MAN (Cunningham, 1903, p. 411)

Origin.—Back of the body of the pubis, pelvic fascia and spine of ischium.

Insertion.—(1) Into central point of the perineum, (2) the external sphincter ani, (3) sides of the lower sacral and coccygeal vertebrae.

The levator ani is divisible into four parts — pubo-rectalis, pubo-coccygeus, ilio-coccygeus and ilio-sacralis.

Innervation.—Perineal (muscular) branches of pubic nerve, and, on its pelvic surface, by special branches from the third and fourth sacral nerves.

CAT (Reighard and Jennings, 1902, pp. 137–138)

"Ilio-caudalis," levator ani.

Origin.—"Along the ventral half of the medial surface of the ilium, caudad of the sacrum."

Insertion.—"By a flat tendon into the ventral surface of the caudal vertebrae, from the second or third to about the seventh."

HYPSPYRMYNODON (Carlsson, 1915, p. 27)

Remark.—"Der M. pubo-coccygeus und der M. ileo-coccygeus sind dicht an einander gelagert und enden im vorderen Teil des Schwanzes."

VARIOUS MAMMALS (Cuvier and Laurillard, *Planches de Myologie*)

U¹ Iléo-sous-caudien (iléo-coxygien).

X¹ Pubo-sous-caudien (pubo-coxygien).

REPTILES

Aftermuskeln (Gadow, 1882, p. 365)

A group of muscles in the cloacal region derived from the lateral muscle of the tail (ischio-caudalis).

Sacro-coccygeus inferior (R^1) (Fig. 8, A^2 , A^1)

Cuvier and Laurillard (*Planches de Myologie*)

Flexor caudæ longus Reighard and Jennings

Flexor caudæ externus Parsons

UNGULATES (Windle and Parsons, 1903, p. 266)

Origin.—Posterior sacral and anterior caudal spines. (Part of the great muscular sheet which lies between the ectogluteus and the true biceps).

¹ Symbols used by Cuvier and Laurillard. Cf. Fig. 8 and p. 506.

Provisional Homologies of the Pelvic Muscles in Reptiles, Birds, and Mammals

Innervation from	Sphenodon (Osawa, Gadow)	Alligator (Gadow)	Ostrich (Gadow)	Monotreme (Westling)	Placental (Cunningham)
<i>Nn. iliopect.</i>	Pubi-ischio-trochantericus-int. (Osawa)	Pubi-ischio-femoralis int.	Ilio-femoralis-internus (Gadow) Ilio-trochantericus partim	{ Pectineus Iliacus Psoas major	Pectineus Iliacus Psoas major
<i>Plexus cruralis (N. femoralis)</i>	Extensor triceps Ambiens	Ilio-tibialis internus { Femoro-tib. Ambiens (2 parts)	Sartorius Femoro-tib. Ambiens (2 parts)	Sartorius Quadriceps Rectus fem.	Sartorius Quadriceps Rectus fem.
<i>Nn. a + b</i>	Ilio-tibialis Coccyg. fem. brev.	Ilio-tibialis I Caudi-ilio-fem.	Ilio-tibialis externus Caudi-ilio-fem.	Gl. max. ?	Glut. max. Agitator caud. Pyramidalis Pyriformis
<i>Nervus obturatorius</i>	Pubi-ischio-tibialis Pubi-ischio-femoralis (Osawa)	Absent { Ischio-femoralis (Gadow) Pub. ischio-femoralis externus (Gadow)	Absent Absent Pub. ischio-femoralis Add. mag. avium ¹ Obturator + Accessorii	Gracilis { Add. long. Add. brevis Add. mag. Absent N. obt. externus	Gracilis Adductor longus Adductor brevis Adductor magnus Absent N. obt. Obturator ext.

¹ The "adductor magnus" of birds (= pubi-ischio-femoralis, Gadow) does not appear to be homologous with any of the adductor series of mammals, since

Innervation from		SPHENODON (Osawa, Gadow)	ALLIGATOR (Gadow)	OSTRICH (Gadow)	MONOTREME (Westling)	PLACENTAL (Cunningham)
<i>Plexus ischiadicus</i>		Ichio-trochantericus (Osawa)	Pub. isch. fem. post. (Gadow)	Ichio-femoralis ²	Quad. femoris <i>N. tibialis</i>	Quadr. femoris Gemellus inf. Obturator int. Gemellus sup. <i>N. tibialis</i>
		Ilio-femoralis	<i>Pla. isc. + cr.</i> Ilio-femoralis [part]	Ilio. fem. ext. + Ilio-trochantericus [part]	Gluteus minimus <i>N. glut. sup.</i>	Gluteus minimus Gluteus medius Tensor fasc. fem. <i>N. glut. super.</i>
		Ilio-fibularis	Ilio-fibularis (I) Ilio-fibularis (II)	Ilio-fibularis	Biceps <i>N. to hamstring muscles</i>	Tenuissimus (Bic. cap. brev.) <i>N. to bic. access.</i> Biceps femoris (cap. long.)
		Ichio-tib. posticus	Flex. tib. ext. Flex. tib. int.	Caud. ilio-flexorius Ischio-flex.	Semitend. Semimemb. <i>N. to hamstring muscles</i>	Semitendinosus Simemembranosus <i>N. to hamstring muscles</i>
		<i>Nn. isc. tib.</i>				

² The "ischio-femoralis" of birds appears to be homologous rather with the pubi-ischio-femoralis posterior of reptiles than with the ischio-femoralis of reptiles [W. K. G.].

Insertion.— Chiefly into the outer side of the patella; above and below this it blends with the fascia.

Innervation.— It is supplied by the same nerve as the ectogluteus (inferior gluteal).

CAT (Reighard and Jennings, 1902, p. 138)

Origin.— “Ventral surface of the last lumbar vertebræ, of the sacrum, and of the transverse processes of the caudal vertebræ.

Caudad the muscle forms long, strong tendons. . . .”

Insertion.— On ventral surface of the caudal vertebræ.

ORNITHORHYNCHUS (Cuvier and Laurillard, Planches de Myologie, Ornithorhynque, Pl. 269, figs. 1, 2, R¹)

Provisional Homologies of

MAN (H. H. Wilder)	VARIOUS MAMMALS (Cuvier and Laurillard)	CAT (Reighard and Jennings)	PETROGALE (Parsons)
Sacro-coccygei posteriores (ex- tensor coccygis)	(T) Interépineux supérieur	Extensor caudæ medialis	Extensor caudæ internus
	(R) Sacro-coxygien supérieur	Extensor caudæ lateralis	Extensor caudæ externus
Abductor caudæ dorsalis	(Z) Intertransversaires	Abductor caudæ externus	Abductor caudæ internus
Abductor caudæ ventralis (coc- cygeus)	(Q) Ischio-caudien (ischio- coxygien externe)	Abductor caudæ internus	Abductor caudæ externus
Sacro-coccygei anteriores	(R') Sacro-coxygien inférieur	Flexor caudæ longus	?Flexor caudæ externus
	(V) Sous-caudien (interépi- neux inf.)	{ ?Flexor caudæ brevis [?Flexor caudæ profundus	{ Flexor caudæ internus ?Flexor caudæ profundus
Levator ani group	(U) Iléo-sous-caudien (iléo- coxygien)	Ilío-caudalis	
(in part)	(X) Pubo-sous-caudien (pubo- coxygien)	Levator ani	

"*Depressor caudæ*" (Coues, 1870, p. 135)

Origin.— Inside of pelvis behind acetabulum and at junction of ilium with sacrum.

Insertion.— Apices and ventral surfaces of transverse processes of all caudal vertebræ.

REPTILES

?Part of *caudi-femoralis*

Remark.— The position of this muscle in mammals seems to point to its derivation from the caudi-femoralis. It is also immediately behind and below the pyriformis which was derived from the caudi-ilio-femoralis.

the Chief Tail Muscles

HYPSPRYMNODON (Carlsson)	ALLIGATOR (Gadow)	SPHENODON (Osawa)
Levator caudæ internus	} M. caudæ dorsalis	} Coccygeo-iliacus
Levator caudæ externus		
Intertransversarii	Ilio-caudalis	
Ischio-coccygeus	Ischio-caudalis	Coccygeo-ischiadicus
Sacro-coccygeus ("Flexor caudæ externus Par- sons")	} ?Part of caudi-femoralis	} ?Part of coccygeo-femoralis longus
Flexor caudæ profundus		
Interaccessorii		
Ilio-coccygeus	} "Aftermuskeln" (from ischio-caudalis)	Coccygeo-ischiadicus (partim)
Pubo-coccygeus		

DISCUSSION

By W. K. Gregory

A discussion of the musculature of the shoulder-girdle of *Cynognathus* may be facilitated by reviewing the chief characters in the shoulder-girdle and humerus which contrast *Sphenodon*, a primitive crawling reptile, with man, a highly specialized bipedal mammal.

Sphenodon

Scapula vertical.
 Scapulocoracoid fastened to sternum.
 Clavicle immovably fastened to sternum and to scapula.
 Interclavicle present.
 Coracoid of large size, pierced by the supracoracoid foramen.
 Epicoracoid continuous to clavicle, shutting off the space medial to the scapulocoracoid from the outside.

 Anterior border of scapula in its primitive position.
 No prespinous (supraspinatus) fossa.

 Glenoid facing outward and backward, borne equally by scapula and coracoid.

Homo

Scapula recumbent over ribs.
 Scapulocoracoid free from sternum.
 Clavicle movably fastened to sternum and to acromial process.
 Interclavicle absent.
 Coracoid small or vestigial, not pierced by foramen.
 Epicoracoid absent or perhaps represented by the sternoclavicular ligament; a wide communication between the space medial to the scapulocoracoid and the outside.
 Anterior border of scapula reflected externally, forming the spina scapulæ.
 Prespinous (supraspinatus) fossa widely developed.
 Glenoid facing chiefly downward and forward, borne chiefly by scapula.

The chief contrasts between the humeri of *Sphenodon* and man are as follows:— first, in man, the great extension, subspherical development, and inward growth of the head of the humerus, which now faces more inward and backward; second, the appearance of a distinct “greater tuberosity” for the insertion of the supra- and infraspinatus muscles at the upper end of the deltoid crest, or processus lateralis; third, the extension of the deltoid crest down the shaft and the subsidence of it except at the lower end where it widens out; fourth, the approximation of the greater tuberosity toward the lesser tuberosity (processus medialis) and the formation of a bicipital gutter; fifth, the enclosure of the tendon of the long head of the biceps of man within the capsule of the shoulder-girdle; sixth, the further differentiation of the distal facets of the humerus (which is correlated with the freer power of pronation and supination) and their position more on the end than on the side of the shaft (which is connected with the upright pose).

These osteological differences between *Sphenodon* and man are associated with equal differences in the musculature. In *Sphenodon* the scapula and suprascapula have a relatively great area for the insertion of muscles connecting the shoulder-girdle with the body (including the trapezius, or cucullaris, the levators, the omotrachelian, the serrati, and the subscapularis), while the area for the scapulo-humeral muscles is relatively restricted. The areas for the coracohumeral muscles, both ventral and dorsal to the coracoids, are extensive. In man, on the other hand, the areas on the scapula for the body muscles are restricted chiefly to the margins of the scapula and to the subscapular surface, while the scapulohumeral muscles are greatly enlarged and occupy not only the medial and lateral surface behind the spine but also a great new area, the supraspinatus fossa in front of the spine, which is not at all developed in *Sphenodon*.

These osteological and myological differences between *Sphenodon* and *Homo* are naturally correlated with equal contrasts in the pose: *Sphenodon* retains the primitive reptilian pose of the fore limbs, in which the elbows are widely everted, the arms being held akimbo; while man has gone even beyond the normal mammalian position in which the elbows are drawn in to the flanks, and, in consequence of his upright position, has also opened up the angle between the humerus and the fore limb.

The wide contrast between the primitive reptile *Sphenodon* and the highly specialized placental mammal, *Homo*, in the form of all the elements, in the arrangement of the muscles, and in the pose of the fore limbs, is mediated by the conditions in the living monotremes. These, indeed, more nearly resemble *Sphenodon* than *Homo* in the general form of the shoulder-girdle. Their scapulocoracoid is well fastened to the sternum and is not reflected over the ribs (except in its posterosuperior angle) but is even inclined forward; the clavicle is immovably fastened at both ends; an interclavicle is present; the glenoid is shared equally by the scapula and coracoid and faces more outward than downward; the epicoracoid is largely developed. The prespinous fossa is not yet developed and the supraspinatus muscle is still near its primitive position, associated with the coracoid muscles. In the arrangement of other muscles, also, the monotremes, in many respects, stand in the reptilian stage. The muscles connecting the scapula with the body are very strongly developed, especially the omotrachelian and so-called levators of the scapulæ, almost as well as in reptiles.

On the other hand, the monotreme shoulder-girdle shows an important advance toward the human type in the reflection of the anterior border to form the spina scapulæ (Wilson and McKay), in the development of a large fenestra between the epicoracoid, acromion, and the clavicle, in the reduction of the anteroposterior diameter of the coracoid, and in the loss of

the supracoracoid foramen. The muscles connecting the scapula with the humerus become greatly developed, especially the infraspinatus and the subscapularis. Some presumably aberrant specialization also takes place, especially in the extension of the subscapular area on to the posterosuperior and posteroexternal region of the scapula.

The humerus of monotremes loses but little of the primitive reptilian habitus, the chief advances in the mammalian direction being the further differentiation of the head, the inclination of the head to the long axis of the bone, the development of a distinct greater tuberosity, and the sharp twisting of the shaft.

The pose of the fore limbs of monotremes is essentially reptilian, although the articulations between the scapulocoracoid and the humerus and between the humerus and the forearm are more completely differentiated.

With this comparison of *Sphenodon*, *Homo*, and the monotremes in mind, we are in a position to evaluate the characters of the shoulder-girdle and humerus of *Cynognathus* (Pls. XLI, XLII). In these parts the reptile *Cynognathus* is naturally much closer both to *Sphenodon* and to the monotremes than to *Homo*, since the scapulocoracoids were fastened to the sternum and a wide interclavicle and stout clavicles were present (Broom). In the shoulder-girdle *Cynognathus* is almost intermediate between *Sphenodon* and monotremes. Thus, it shares with *Sphenodon* the primitive reptilian character of the upper end of the scapula, while it resembles monotremes in the sharp reflection of the anterior border to form the spina scapulæ, which ends below in the acromial process for the clavicle. The coracoid region is on the whole nearer to the monotreme type in general form, but very probably differed in the lack or feeble development of an epicoracoid fenestra. Both the pro- and the metacoracoids of the primitive Permian reptiles are retained, but the coracoid mass as a whole is functionally analogous with that of monotremes and the general position of the coracoscapular arch could not have been very dissimilar to the monotreme type, to which it presents a general resemblance in all views. The posterior border of the scapula differs from both the monotreme and the *Sphenodon* type in being sharply reflected and flattened posteriorly.

The humerus of *Cynognathus* and of its relative, *Gomphognathus*, differs from the monotreme type in the sessile position and flattened form of the head, which was located entirely on the top of the shaft as in primitive reptiles and was less sharply inclined inward. The greater tuberosity has not yet been differentiated from the deltopectoral crest (processus lateralis) and the lesser tuberosity (processus medialis) is somewhat less developed than in the monotremes; the same is true of the entocondylar expansion at the distal end. The shaft of the humerus is not so sharply twisted and bent

upon itself as in the monotreme type. Therefore, in all these features the humerus of *Cynognathus* was more primitive and somewhat more reptilian than that of monotremes.

Accordingly, the shoulder-girdle and humerus of *Cynognathus* approach the monotreme type in certain respects and in others are prevailingly reptilian. This fact enables us to infer with some approach to accuracy the general character and arrangement of the musculature. The scapulocoracoid of *Cynognathus* was extremely small as compared with the size of the skull so that the heavy muscles running along the side of the neck from the scapula to the occipital region and along the flanks from the back of the scapula to the ribs were of necessity relatively large in proportion to the size of the scapula; that is to say, the omotrachelian and levators must have filled the whole of the anterior surface of the spina scapulæ¹ for the support of the heavy head, while the opposing muscle, the serratus superficialis, must have been powerfully developed, as is indicated by the flattening and eversion of the posterior border.

It was at first a question whether the postspinous fossa was fully occupied by the infraspinatus muscle (= scapulo-humeralis), as it is in mammals, or whether this fossa was partly filled by the dorsalis scapulæ (deltoides scapularis), as it is in the alligator. In favor of the former view is the rather marked resemblance of this region to the monotreme type and the fact that when the humerus is articulated with the scapulocoracoid the postspinous fossa is in the proper position to support a powerful muscle running down to the posterosuperior surface of the great deltoid crest. Similarly, it was a question whether the medial surface of the scapula was largely taken up by the deep serratus anterior muscles or whether the subscapularis had already extended dorsally, limiting the serratus to the upper end of the scapula. In favor of the latter view is the vigorous development of the internal, or lesser, tuberosity (processus medialis) of the humerus where the subscapularis muscle was inserted. A long rugosity on the posterior border of the scapula just above the glenoid is interpreted as the area of origin for the scapular head of the triceps, while the smaller rugosity immediately below this may well mark the place of origin of the teres minor. The origin of the supraspinatus muscle is placed in our restoration below the acromial region, because the wall of bone at this point would prevent the supraspinatus from finding its way through the epicoracoid fenestra and up onto the anterior surface of the spina scapulæ.² Even in *Ornithorhynchus*, where there is a

¹ This is also the conclusion of D. M. S. Watson (Journal of Anatomy, Oct. 1917) whose paper was received some time after the present manuscript was completed.

² Watson (*op. cit.*) comes to the same conclusion.

large epicoracoid fenestra, the supraspinatus has not yet driven out the omotrachelian and levators from the anterior surface of the spine.

At the upper end of the scapula a roughened border indicates the attachment of a stout suprascapula which probably gave insertion to the serratus anterior, to part of the trapezius and perhaps at its anterior corner to the rhomboideus. The sharply reflected spine must have given attachment on its outer border to the stout trapezius and to the spinous portion of the deltoid. Its anterior surface doubtless gave attachment for the omotrachelian and levators, while its posterior surface probably bounded the massive infraspinatus.

The muscles of the coracoid region must have been similar to those of monotremes, first, because of the general similarity of the osseous elements of this region and, secondly, because there is a fundamental agreement in the musculature of the coracoid region even between *Sphenodon* and monotremes.

Possibly the most conjectural features of the restoration of the pectoral region are the position and differentiation of the rhomboideus, which is developed only in the crocodilians among recent reptiles but is well developed in monotremes. We represent it as being associated with the levator scapulæ profundus, from which it may have been derived.

Passing to a consideration of our restoration of the pelvic musculature we may again approach the subject by a comparison of the two extremes, *Sphenodon* and *Homo*, as follows:

Sphenodon

Ilium rod-like, inclined somewhat backward behind acetabulum, with very small gluteal area and large posterior border for attachment of large tail muscles.

Pubis and ischium relatively large.

Pubis much produced in front of acetabulum.

Acetabulum relatively large, subtriangular in outline.

Femur with oval head on top of shaft.

Femur with no distinct external trochanter.

Internal trochanter facing downward and inward.

Homo

Ilium widely expanded transversely, produced in front of acetabulum, with much enlarged gluteal and iliacus areas. Area for vestigial tail muscles very small.

Pubis relatively small.

Pubis but little produced in front of acetabulum.

Acetabulum small and subcircular, closely surrounding head of femur.

Femur with spherical head, sharply inclined inward and separated from the shaft by a distinct neck.

Great trochanter of large size located at the top of the shaft.

Lesser or internal trochanter facing upward and inward.

These broad contrasts are naturally associated with differences in the normal pose of the hind limb, the sprawling pose of the primitive reptile contrasting widely with the erect walking and standing pose of man. In this connection it may be noted that, with the possible exception of some tortoises, reptiles apparently do not stand still for any great length of time; they either move forward or settle down to rest. Consequently, modern reptiles show no special adaptation for maintaining the standing pose, so far as the writer has observed.

Perhaps the most important differences in the musculature of the two forms are as follows: in *Homo* the gluteal area is greatly expanded and the insertions of the primitive tail muscles are greatly reduced or absent. The iliacus area on the front inner side of the ilium is also widely expanded. A group of muscles including the psoas major, iliacus, and pectineus muscles has very probably been derived from the pubi-ischio-femoralis internus mass, the principal change being the loss of the posterior portion of the mass extending over the inner surface of the ischium. The general functions and distal attachments of these supposedly homologous groups in reptiles and mammals are similar and they are innervated from similar or homologous nerves and plexuses. (See page 504).

As in the structure of the fore limb, the monotremes again mediate the differences between *Sphenodon* and *Homo*, although they favor the latter in certain important characters, especially in the position and musculature of the ilium.

Cynognathus, in turn, divides the difference between *Sphenodon* and the monotremes; and a comparison of its pelvis (Pl. XLVI) and femur with those of *Sphenodon*, alligator, and ostrich, yields evidence as to the placing of the principal muscle groups. In the form and relations of the ilium *Cynognathus* approaches the alligator in some respects, the monotremes and the ostrich in others. It agrees with the alligator in the backward prolongation of the ilium behind the acetabulum, with the monotremes in the forward growth of the ilium in front of the acetabulum. The posterior tip of the ilium probably gave insertion to the ilio-caudalis (= abductor caudæ dorsalis) muscles, as in reptiles generally, while the greatly expanded blade of the ilium denotes a corresponding expansion of the ilio-femoralis, which is homologous with the deep glutei of mammals. The great enlargement of the external trochanter on which this muscle was inserted also supports this interpretation. On the superior border of the ilium the gluteus maximus probably arose, comparable with the ilio-tibialis externus of alligator and ostrich. (In monotremes the gluteus maximus does not touch the ilium, as it lies entirely above the pelvis.) The ilio-tibialis internus (= sartorius) probably arose near the anterior margin of the blade of the ilium in front of the gluteal area.

The medial anterior surface of the blade of the ilium probably gave origin to the upper part of the pubi-ischio-femoralis internus. The quadratus lumborum, along with the pubi-ischio-femoralis internus, may possibly have extended down to the femur as in the alligator.

The ilium, on the whole, was decidedly more advanced toward the monotreme type than is that of *Sphenodon*.

In the construction of the pubi-ischiadic plate *Cynognathus* is much closer to the monotremes than to either *Sphenodon* or alligator, differing from that of monotremes chiefly in the smaller size of the obturator fenestra. The pubis is located almost directly beneath the acetabulum and is not widely produced in front of it as in *Sphenodon*. The ischium and pubis in other characters also suggest those of *Echidna*.

The acetabulum is very large and, as in primitive reptilian types, it extends superiorly on to the under surface of a prominent overhanging process of the ilium, a condition foreshadowing the monotreme type.

The femur (Pl. XLVIII) differs from those of typical reptiles in having a much enlarged great trochanter, indicating a corresponding development of the deep glutei; the medial or lesser trochanter is a low process at the upper end of a long low ridge on the medial surface of the femur in its upper half of the shaft. The ridge perhaps represents the adductor crest, or linea aspera; the process probably gave insertion to the pubi-ischio-femoralis internus. Accordingly, it seems probable that the femur could be turned fairly well forward and the knees more or less straightened out in running and, further, it seems likely that the pubi-ischio-femoralis internus had already begun to differentiate into the pectineus, iliacus, and psoas major, as in monotremes and other mammals.

On account of the general similarity of the pubi-ischiadic region (Pl. XLV) to that of *Ornithorhynchus*, the arrangement of the gracilis, adductors and obturator externus on the pelvis must have been substantially the same as in the monotreme type. The posterior process of the ischium probably gave insertion to the biceps femoris, as well as to the ischio-caudalis, semitendinosus, and semimembranosus, as in monotremes, while the dorsal rim of the ischium was very likely covered by the ischio-trochantericus, or pubi-ischio-femoralis posterior, representing the obturator internus + quadratus femoralis + gemelli of mammals, since there is no very essential difference in this region even between types so widely separated as alligator and *Echidna*.

PART II.—A COMPARISON OF THE MUSCLE AREAS OF THE PELVIS OF
ALLIGATOR, STRUTHIO AND ORNITHOLESTES

BY W. K. GREGORY AND C. L. CAMP

The completion of the manuscript of this part was interrupted when the junior author volunteered and was accepted for military duty. It is, however, deemed advisable to publish the accompanying diagrams at the present time and along with the preceding article, with which their subject matter is closely connected.

It will be seen (Pl. XLVI) that, in spite of the general resemblance of the ilium of theropodous dinosaurs to that of birds, their pelvis as a whole is of reptilian type, resembling the birds in the forward extension of the ilium, but differing from them especially in the fact that the pubis has not been turned backward parallel to the ischium. From this it is fair to infer that the pubi-ischio-femoralis internus, the pubi-ischio-femoralis externus, and adjacent muscles were still in their primitive reptilian position. The supposed homologies of the pelvic muscles in reptiles and birds are given in the table on pages 504, 505.

PART III.—NOTE ON THE ORIGIN AND EVOLUTION OF CERTAIN
LOCOMOTOR ADAPTATIONS IN THE PECTORAL AND PELVIC
GIRDLES OF REPTILES AND MAMMALS

BY W. K. GREGORY

The adaptations for forward locomotion in the girdles and limbs of *Cynognathus* have become clearer to the writer after a fairly comprehensive review of the evolution of the locomotor apparatus in the ascending classes of vertebrates.

The earliest or piscine stage¹ in this evolution, as well as the general principles of quadrupedal locomotion and the mechanism of the limbs in mammals have been discussed in earlier papers, from one² of which may be cited the following paragraphs.

¹ Gregory, W. K. 1915. Present status of the problem of the origin of the Tetrapoda. *Ann. N. Y. Acad. Sci.*, XXVI, pp. 338-369, 375-376.

² Gregory, W. K. 1912. Notes on the principles of quadrupedal locomotion and on the mechanism of the limbs in hoofed animals. *Ann. N. Y. Acad. Sci.*, XXII, p. 270.

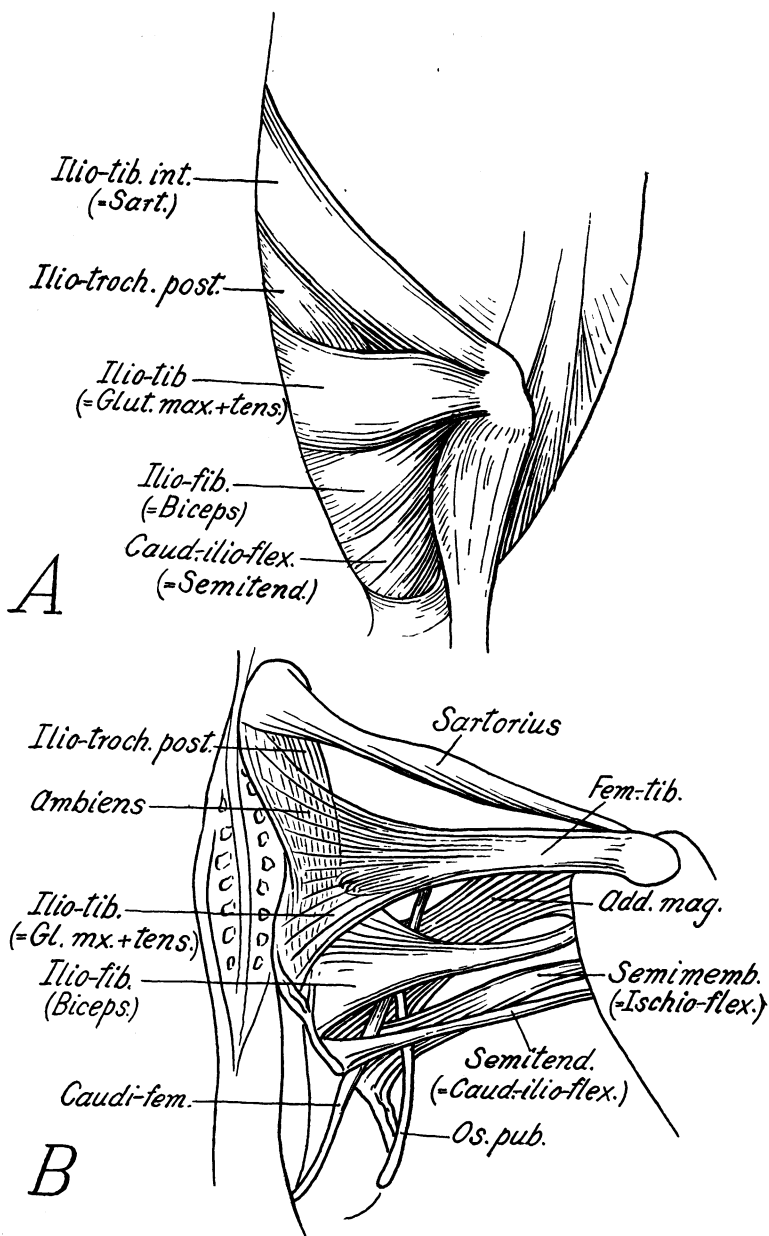


Fig. 9.

In the stegocephalian stage of quadrupedal locomotion, the short limbs were held outward from the body, the humerus and femur were very short and the feet were spreading and flat. Crawling was effected in part by a sharp downward pull of a proximal segment (humerus or femur), thus tilting the body upward on the same side and throwing the weight on the opposite foot. The long axis of the body was meanwhile thrown into alternate lateral curves, the advancing fore limb being on a convexity, the advancing hind limb on a concavity.

In the late reptilian or early mammalian stage, the feet were brought around partly under the body, the elbow and knee began to be drawn in, the scapula was rotated backward as the coracoid lost its connection with the sternum, and the body became well raised off the ground. According to a hypothesis advanced elsewhere by the writer,¹ this process was associated with the acquisition of climbing, or semi-arboreal, habits, structural vestiges of which remain in the partly divergent first digit and many other characters of early Eocene mammals.²

Two corrections should be made in the first paragraph: first, the humerus of primitive tetrapods does not pull so much directly downward as obliquely downward, forward and backward; secondly, the advancing fore limb is just in front of a convexity and the advancing hind limb just behind a concavity.

We may begin with a brief discussion of the origin and evolution of the pelvis and hind limbs in reptiles because, for reasons noted below, the evolution of the hind limbs is in some ways easier to understand than that of the fore limbs.

In the remote piscine ancestors of the tetrapod vertebrates forward locomotion was doubtless accomplished partly through lateral undulations of the body, induced by the metameric muscles and transmitted to the tail, partly through paddle-like movements of the pectoral and pelvic limbs. These limbs were the result of nodal outgrowths and subsequent concrescence of metameric muscles, nerves, and cartilages. Hence, in the earlier stages of locomotion, the movements of the paired limbs were closely correlated with, and at first subordinate to, the undulatory movements of the axial skeleton and musculature, while in the highest stages the limb movements and musculature become widely differentiated from those of the axial skeleton. At the same time the originally metameric character of the limb

Fig. 9. A. Superficial muscles of the pelvis of *Eudyptes chrysocome*. From Gadow and Selenka, after Watson.

B. Muscles of the pelvic limb of *Larus fuscus*. From Gadow and Selenka, after Selenka. Muscle names according to Gadow.

The homologies of these muscles are indicated in the table on pages 504, 505.

¹ 1910. The orders of mammals, *Bull. Amer. Mus. Nat. Hist.*, XXVII, p. 226.

² Matthew. 1904. Arboreal ancestry of the Mammalia, *Amer. Nat.*, XXXVIII, pp. 811-818.

muscles is progressively disguised in various degrees, some muscles, like the quadratus lumborum, pubi-ischio-femoralis internus, and caudi-ilio-femoralis of reptiles, retaining clear traces of their metameric character, while many others lose it almost entirely.

THE PELVIC LIMBS

In primitive amphibians and reptiles (cf. Pls. XLIII, XLVII) and even in dipnoan fishes the pelvis functions as a bony base located at the intersection of three main series of muscles: first, an anterior series running from the front part of the pelvis and proximal part of the limb along the backbone and flanks (here belong the sacro-spinal muscles, the quadratus lumborum, pubi-ischio-femoralis internus, and abdominal muscles); secondly, a posterior series running from the back part of the pelvis and femur along the tail (including the caudi-ilio-femoralis, caudi-femoralis, ilio-caudalis, ischio-caudalis); and, thirdly, a transverse series running outward from the pelvis to the limb both above and below the femur.

These transverse muscles running from the pelvis to the limbs are arranged in two or more concentric cones, the outer layer, running from the periphery of the pelvis to or near the knee joint, includes on the outer side the sartorius, gluteus maximus, biceps, semimembranosus, semitendinosus, etc., and on the inner side the gracilis; the deeper layers running from the deep surfaces of the pelvis to the more proximal surface of the shaft of the femur include the adductors and obturators, below the acetabulum, and the deep glutei above it. Thus in *Sphenodon* and in lizards, which retain the primitive reptilian condition, the rod-like ilia function as a fixed base, or fulcrum, between the muscles that bend the lumbar region and those that bend the tail. The muscles that run outward from the blade of the ilium to the thigh originate between and below the longitudinal muscles.

In the primitive pro-tetrapod the ventral part of the pelvis, or pubi-ischiadic plate, was doubtless of large size and strongly developed, while the ascending blade, or ilium, was small. The contact of the pelvis with the sacral rib or ribs was very loose and ligamentous. The ventral muscles, running from the under side of the femur to the outer side of the pubis and ischium, were strongly developed, as were also the muscles running from the femur backward along the tail and from the femur forward to the flanks; but the muscles running from the upper surface of the femur to the ilium were feeble. The deep gluteal muscles are specialized anterior portions of the lateral tail muscles and probably served at first rather to abduct the tail than to move either the femur or the pelvis. The superficial gluteal muscles

(ilio-tibialis) on the other hand, are derived from the obliquus abdominis externus (Gadow, 1882).

All this was related to the fact that in this stage of evolution the adaptations for preventing the body from settling down of its own weight on one side, when one foot was raised from the ground, were less perfectly developed than in later types which can raise the body far from the ground and even hold it for some time in a true standing pose. When a quadruped lifts, for example, the left hind limb off the ground, the right hind foot being firmly on the ground, the backbone and sacral region are only prevented from sagging toward the left by the action of those muscles on the right side both above and below the acetabulum which tend to pull the pelvis and backbone toward the head of the right femur. In this way, also, the sacral ribs are being forced downward and outward against the inner side of the ilium. As long as the animal remains small and the body is not raised high above the ground, especially if the connection with the sacral ribs is loose, the lifting effect can be obtained by the muscles running from the neural spines of the backbone to the top of the ilium, and from the upper border of the ilium to the knee joint, as well as by the ventral muscles running from the pubis and ischium to the femur; but, when the size becomes very great and when the body is lifted well above the ground, these muscles are reinforced by the greatly expanded gluteal mass, running from the outer surface of the ilium to the upper part of the femur. Hence, at this more advanced stage, the area on the blade of the ilium for the gluteal muscles is correspondingly expanded.

Thus the primitive reptilian ilium was probably directed backward, its posterior tip serving as a base for the powerful ilio-caudalis, its blade for the caudi-ilio-femoralis muscles. In this type of pelvis, seen in *Sphenodon*, *Varanops*, and the lizards, the thorax is usually not large and the limb bones not very stout. The space for the ilio-femoralis (deep gluteal) muscles is restricted. In heavy-bodied forms with stout limbs, on the other hand, such as *Casea*, *Moschops* (Pl. XLVII), *Cynognathus* (Pl. XLVI), and *Dicynodon*, the blade of the ilium expands anteriorly, greatly increasing the areas for the deep gluteal (ilio-femoralis) muscles. This anteroposterior expansion of the ilium culminates in the birds and dinosaurs, which have correspondingly extended gluteal muscles, for preventing the sagging of the body, as well as for moving the opposite femora.

In *Cynognathus* the expansion and forward extension of the gluteal surface was well advanced, but the subsequent narrowing of the ilium, which is so characteristic of the ilium of primitive mammals, had not yet supervened.

In fully aquatic reptiles, on the other hand, the weight of the body being

largely buoyed by the water, there is less need for counteracting the tendency to sag on one side when the femur of that side is raised. Hence, in the more specialized aquatic reptiles, that is those that swim chiefly by means of the tail rather than of the limbs, the muscles that tend to press the pelvis and backbone against the femur are small or more or less reduced. Thus we have an adaptational reason both for the reduction of the ilia and loosening of the sacrum in fully aquatic types and for the opposite expansion of the ilium and extension of the sacrum in animals that hold the body well raised from the ground.

In forward locomotion, both on the ground and in swimming, the pelvis as a whole is turned from side to side and rocked in a transverse plane. There is always a special cooperation of groups of muscles of the opposite sides: on one side above the acetabulum, on the other side below it, and on one side in front and on the other side behind it. For example, some of the inferred movements of the pelvis and femora of a reptile may be considered, beginning at the moment when the left hind limb is directed backward as far as possible and the right hind limb is directed forward, both hind feet being on the ground. At this moment on the left side a group of muscles running from the left femur backward to the ischium and to the tail and from the left ilium and ischium to the tail are in a state of maximum tension, while on the right side the corresponding sets of muscles are relaxed. The resulting tendency to turn the pelvis toward the left is probably reinforced by the tension of muscles on the right side lying in front of the pelvis, such as the *quadratus lumborum*, *ilio-costalis*, and *obliquus abdominis*. But, at the same time the pelvis has also been tilted vertically toward the left side, through the tension of the right ventral muscles running from the under side of the pelvis to the femur and of the left dorsal muscles running from the left ilium to the femur, as well as from the thrust of the left femur.

In reptiles which are able to straighten fully the knee joints (the primitive Permian types had permanently crooked knee joints) the turning of the pelvis toward the left is probably checked and the opposite movement begun by the thrust of the left femur upon the acetabulum, due to the straightening of the left knee joint at the end of the backward stroke of the left hind limb. This tends to push the pelvis toward the right. The left femur is then drawn forward, the right femur backward, the whole pelvis and sacrum meanwhile turning from left to right upon the articular facets of the posterior lumbar and anterior caudal vertebræ. The powerful *caudi-femoralis* and *caudi-ilio-femoralis* muscles serve not only to vibrate the tail but alternately to check and reinforce the muscles that draw the opposite femora forward and backward.

In primitive mammals the ilium has grown forward in front of the ace-

tabulum and the pubis and ischium have been prolonged behind and below it. In this way the gluteal muscles above the femur and the obturators and adductors below the femur by an extension of function serve not only to twist the pelvis and to prevent collapse when one limb is lifted but also to draw the femora more directly backward and forward. This is associated with a progressive forward turning of the femur, so as to bring the knees in toward the flanks and the feet nearer to the mid line. In the highly specialized graviportal mammals, which have straightened the limbs at the knee-joint so as to transmit the weight more directly through the post-like limbs, the blade of the ilium has become expanded in a nearly transverse direction and at right angles to its original position. In these forms, again, the expanded gluteal and iliac muscles function as much to overcome the tendency to collapse when one foot is raised from the ground as to move the femur of the advancing limb. In man, also, a similar transverse expansion of the ilium with a correlated expansion of the gluteus maximus serves a similar purpose.

The foregoing transformation of the primitive reptilian pelvis into the specialized mammalian types has been accompanied by a marked differentiation of a great muscle mass known as the pubi-ischio-femoralis internus, which originates on the inner-upper surface of the pubis and ischium and beneath the sacral vertebræ and, passing forward over the anterior rim of the pubis and running backward, is inserted usually on the upper part of the femur. The dorsal portion of this mass, in the mammals, extends upward and forward along with the forwardly growing ilium and gives rise to the iliacus and psoas muscles, which powerfully aid in pulling the femur forward and inward. The tail muscles of typical mammals, on the other hand, lose much of their locomotive function, the tail becoming sharply constricted from the body and the caudi-femoralis and caudi-ilio-femoralis reduced and broken up into fragments such as the caudi-femoralis and the pyriformis. Thus the pubis and ischium of mammals finally came to lie chiefly behind the acetabulum, and the adductors and obturators tend to pull the femur backward as well as inward.

In birds, also, the ilium (Pl. XLVI) has grown forward, producing a corresponding extension of the gluteal areas, while the pubis and ischium also have been produced behind the acetabulum. The pubis, however, has become variously reduced, because the pubi-ischio-femoralis externus and related muscles now find their principal attachment on the ischium and the pubis and ischium are both bent backward in order to draw the femur backward as much as inward.

In the ornithischian dinosaurs the expanded prepubic process appears to have served as a base for a forward extension of the pubi-ischio-femoralis

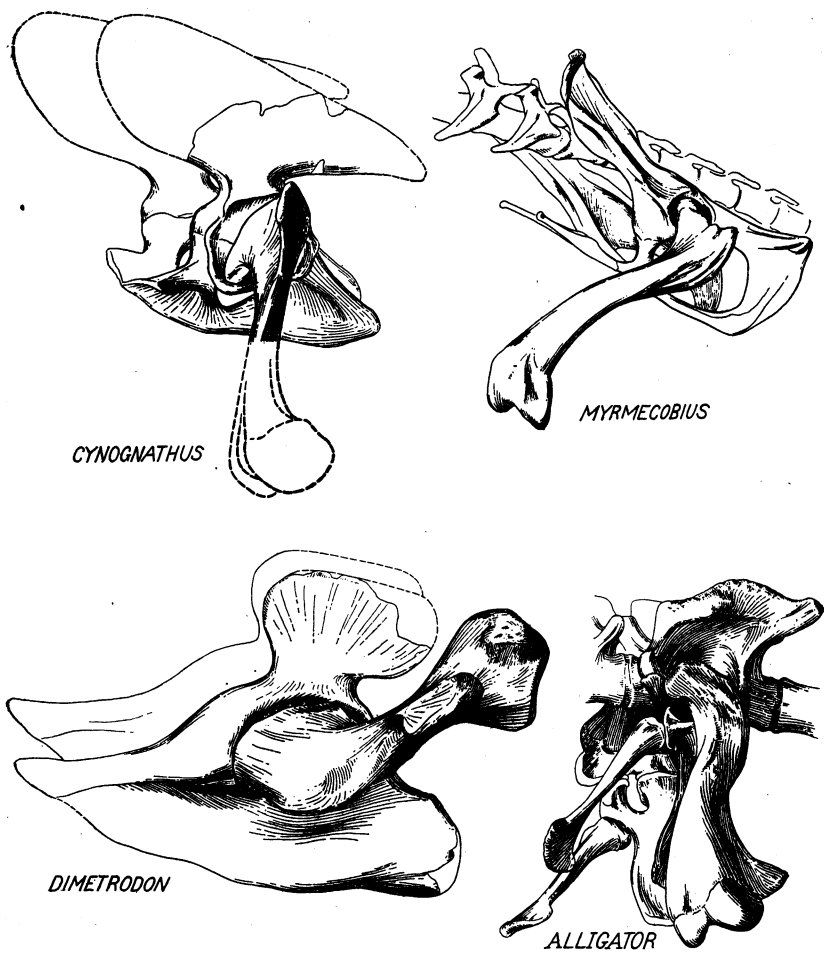


Fig. 1 .

Fig. 10. Form and relations of the pelvis and femur in a primitive reptile and in higher types.

Dimetrodon gigas, Permian of Texas. Pelvis and femur adapted for sprawling gait with sharply bent knees and pes turned partly backward, these characters being also associated with great thickness and strength of the tail. The ilium is chiefly above and behind the wide acetabulum; the pubis is produced in front of it; the wide pubi-ischiadic plate is not fenestrated; the femur was usually directed outward, upward and backward.

Alligator, modernized reptile. Pelvis and femur adapted partly for sprawling gait, partly for running or leaping with body well raised from the ground. Femur can be turned forward, outward and downward. Tail thick and powerful. Pubi-ischiadic plate widely fenestrated; pubis excluded from acetabulum.

Cynognathus, progressive therapsid reptile from the Trias of South Africa. Pelvis and femur intermediate between the primitive reptilian and primitive mammalian stages. Ilium produced in front of acetabulum, pubi-ischiadic fenestra of moderate size. The femur could be directed forward, outward and downward and the body well raised from the ground. Femur with large external trochanter for the attachment of the deep gluteal muscles.

Myrmecobius, a primitive existing mammal. Pelvis and femur adapted for running, with the body well raised off the ground and the knees brought forward near the flanks, the feet being placed well under the body. Ilium widely produced in front of acetabulum and with reduced caudal process, pubis and ischium well fenestrated produced behind acetabulum; femur with large external trochanter.

externus and internus and perhaps also for the ambiens. The quadratus lumborum may have passed above it to be inserted on the femur. In any case, the muscles carried by the prepubic process very probably served both to draw the femur forward and, as adductors, to assist the gluteal muscles in preventing the body from collapsing when the opposite limb was lifted.

In *Cynognathus* the postacetabular region of the pubi-ischiadic plate is more extended than the pre-acetabular part, so that there was some approach to the conditions seen in monotremes.

The acetabulum in primitive reptiles is very large and, being widely open on all sides, it permits the flattened oval head of the femur to assume many different positions. The primitive acetabulum is more or less three-sided, with a wide cotyloid notch at the base. Ligaments, perhaps corresponding to the ligamentum teres, are extended across this notch. The three elements of the pelvis meet in the center of the acetabulum in a triradiate suture, perhaps because this triradiate growth tract is farthest removed from the rigid centers of ossification of the three elements which are above, below, and behind the femur, respectively, each one being placed between opposing sets of muscle pulls. The primitive acetabulum is closed at the bottom but in crocodiles, dinosaurs, birds, and one of the monotremes (*Echidna*) the deepest part of the acetabulum becomes fenestrated. In these cases the open part is covered in life with heavy ligaments, which are probably as strong as the bones themselves.

The thyroid fenestra is analogous with other fenestræ in the skeleton, such as those in the temporal region or that lying between the clavicle and the epicoracoid. In such cases the fenestration appears at the middle part of an insertion area, the borders of the area becoming greatly strengthened. The fenestrated area apparently permits a free expansion and contraction of the muscles, as may be clearly seen in the temporal fenestræ of *Sphenodon*. In *Cynognathus* and other Therapsida the small pubi-ischiadic openings had apparently not yet extended to the mid line and were more comparable with true obturator foramina than with the true thyroid fenestræ of reptiles (Williston).

In Crocodilia and Saurischia the pubis and ischium are prolonged downward below their primitive level, so that in the alligator there is a deep cleft in the muscle masses between the pubis and the ischium. The same was doubtless true of the Saurischian dinosaurs.

The action and pose of the hind limbs in forward locomotion is naturally dependent not only upon the formation and arrangement of the parts of the pelvis and of the pelvic musculature but also upon the form of the femur. In this connection a study of the head of the femur and of the homologies of the various trochanters of reptiles, birds, and mammals has become

necessary (see Part IV below). From this it is seen that the great development of the external or great trochanter of the femur in *Cynognathus* and mammals is correlated with the expansion of the gluteal surface of the ilium, that the primitive internal trochanteric crest gave rise through divergent evolution, on the one hand, to the lesser trochanter of mammals and, on the other hand, to the fourth trochanter of dinosaurs and birds. The primitive internal trochanter gave attachment to the muscles that draw the femur directly inward toward the pelvis and backward toward the tail. In the fourth trochanter the latter set are the most concerned while the lesser trochanter of mammals gives insertion to muscles that draw the femur forward and inward (iliopsoas, pectineus).

THE PECTORAL LIMBS

The fore limb of primitive vertebrates presents many analogies in structure and function with the hind limb. Just as in the hind limbs, there is a set of muscles running from the vertical blade of the girdle posteriorly to the side of the body, another set running from the girdle anteriorly toward the head, and a third set running transversely from the girdle to the proximal limb element both above and below the fulcrum. The chief differences between the fore and hind limb arise from the fact that the pectoral girdle in the piscine stage of evolution was originally attached to the occiput and was associated with the opercular region almost as much as with the pectoral limb itself. The main vertical dermal element, or cleithrum, in fishes is concave anteriorly, conforming to the curve of the opercular region while the true clavicular plate ("infraclavicle") projects forward beneath the throat. Even in the higher vertebrates the dorsal muscle mass (trapezius) is innervated by the spinal accessory nerves, this fact indicating that it once was located near the occiput. The underlying cartilaginous girdle in fishes rarely has a prominent dorsal branch, its scapular portion being usually short (except in the sturgeon and its allies). The ventral, or coracoid, portion of primitive fishes is, on the contrary, of great functional importance and the anterior process of the coracoid extends forward and downward to the mid line. The glenoid region in fishes is placed at the junction of the scapula and the coracoid and faces posteroexternally, just as it does in primitive tetrapods. The muscles of the pectoral fins in the lowest types of fishes still show their metameric derivation but in the higher fishes especially in dipnoans and crossopterygians, extensive concrescence and outgrowth of neural and muscular segments has already taken place. There are muscles for raising (abducting), depressing, protracting, retracting, twisting, and spreading the fins but, as yet, it is difficult to homologize these

in any detail with the limb muscles of tetrapods, although Humphrey (1872) has analyzed the pectoral and pelvic muscles of tetrapods into layers corresponding with similar layers in fishes.¹

When the ancestral tetrapods emerged from fishes and the opercular region became highly modified the cleithrum, which had been the most important dermal element in the fishes, became rapidly reduced, although in the earliest amphibians of the Carboniferous this element was still of considerable size. At the same time the scapular portion of the cartilaginous girdle became greatly developed and finally replaced the cleithrum in functional importance. Meanwhile the pectoral girdle became freed from the skull through the loss of the posttemporal element and the progressive differentiation of the neck. These changes were, no doubt, accompanied by corresponding modifications of the muscles; those running from the scapula to the humerus and the muscles for flexing and extending the limbs becoming greatly enlarged.

Primitive tetrapods still retain much of the piscine mode of undulation of the body in forward progression. This is accomplished partly by the axial musculature and partly through the action of the longitudinal muscles running along the side of the neck to the scapula and from the scapula back to the ribs. Since the opposite scapulocoracoids articulate movably with the sternum and are braced by the powerful interclavicles and clavicles, the pectoral arch and sternum move first as a whole and, secondly, the scapulocoracoids may slip back and forth on the sternum. The sternum forms a sort of shield or box for the pericardium and adjacent structures, as well as a base for the powerful pectoral muscles. The lateral movement of the pectoral arch and sternum as a whole takes place at the ribs, which move more or less freely at the junction of the cartilaginous ribs with the dermal ventral ribs, or gastralia.

The forward turning of the right side of the pectoral girdle and the synchronous backward movement of the left side in primitive reptiles seems to be accomplished somewhat as follows: The right levators of the scapulæ (Figs. 1, 2) and the omotrachelian contract and cooperate with the left serratus superficialis and serratus anterior profundus. This twists the pectoral girdle toward the right. A rocking movement in a transverse vertical plane might be accomplished through the cooperation of the right trapezius with the left pectoralis and coracoid muscles, and especially with the left subscapularis and serratus profundus. The movement toward the right is also assisted by the extension backward of the right fore limb, pushing the right

¹ Watson. *Journ. Anat.*, 1917, p. 61, has recently put forward some interesting opinions on the derivation of the muscles of the forearm in the earliest tetrapods.

humerus forward and upward against the glenoid. The opposite movement is, of course, then initiated through the sudden relaxation of the above named muscles. The left levators and omotrachelian then pull the left scapula forward and the right serrati pull the right scapula backward.

As a result of this lateral undulation of the shoulder-girdle and of the slipping of the coraco-scapula upon the sternum, the reach of the fore limb on each side is correspondingly increased. In this way the fore limbs cooperate with the hind limbs in throwing the long axis of the body into alternate curves, the right fore limb being fully extended forward at the same time that the right hind limb is extended backward and vice versa.

Cynognathus had already lost the cleithrum but, as it retained the primitive interclavicle and as the scapula was fastened both to the sternum and to the clavicle, the general movement of the shoulder-girdle was, no doubt, as described above. When the shoulder-girdle was momentarily fixed by one limb holding fast to the ground the massive levators and omotrachelian would doubtless have assisted in moving the heavy head and neck. This mode of action of the pectoral musculature is retained in the monotremes, which have the opposite scapulocoracoids articulated with the sternum and the superficial neck muscles very heavy. In typical mammals, however, through the freeing of the coracoid from the sternum the whole girdle acquires great mobility with reference to the trunk and the undulating motion of the body is much less conspicuous.

In reptiles and primitive mammals the fore and hind limbs cooperate with each other in the following way: the fore and hind limbs of the same side move in opposite directions; on the other hand the right fore limb moves in the same direction with the left hind limb and vice versa. The backwardly extended fore foot is raised and moved forward immediately before the forwardly extended hind foot touches the ground. This criss-cross movement of the limbs is correlated with alternate lateral bendings and twistings of the thorax, and with corresponding turning and twisting of the girdles, in such a way that the forward and backward reach of the divergent limbs on one side are increased while the convergent limbs of the opposite side are brought still nearer together. Another advantage of this arrangement is that the pull and push of the limb muscles is supplemented by the powerful spiral and spring-like action of the axial musculature, while a third advantage is that by stretching the limbs of the same side in opposite directions the forward thrusts and pulls are brought nearer to the mid line, and thus the speed is increased. Hence, it should and does follow that the faster a reptile moves the narrower is its trackway.

PART IV.—NOTE ON THE MORPHOLOGY AND EVOLUTION OF THE
FEMORAL TROCHANTERS IN REPTILES AND MAMMALS

BY W. K. GREGORY.

In studying the pelvis and femur of *Cynognathus*, *Moschops* and other Therapsida I was led into a review of the morphology of the head of the femur and of the various trochanters. The following series of vertebrates were studied in this connection:

TEMNOSPONDYLI

†*Eryops*

URODELA

Cryptobranchus*Necturus*

ANURA

**Bufo*

COTYLOSAURIA

†*Diadectes*†*Seymouria*†*Propappus*

PELYCOSAURIA

†*Dimetrodon**Ophiacodon**Varanops**Theropleura*

CASEASAURIA

†*Casea*

THERAPSIDA

†*Elurosaurus**Endothiodon*†*Moschops*†*Cynognathus*†*Diademodon**Dicynodon*

RHYNCHOCEPHALIA

**Sphenodon*

CHELONIA

**Testudo*

SQUAMATA

†*Varanus***Iguana**Heloderma**Chamaeleo*

PELYCOSIMIA

†*Erythrosuchus*

PSEUDOSUCHIA

*Aëtosaurus**Ornithosuchus**Thecodontosuchus*

PARASUCHIA

Typothorax†*Mystriosuchus*†*Acomposaurus*

CROCODILIA

*Geosaurus**Dacosaurus***Alligator*

THEROPODA

†*Plateosaurus**Sellosaurus**Anchisaurus*†*Ornitholestes*†*Struthiomimus*†*Allosaurus*†*Tyrannosaurus*

SAUROPODA

Haplocanthosaurus†*Camarasaurus*†*Brontosaurus*†*Diplodocus*

ORNITHISCHIA

†*Iguanodon*†*Camptosaurus*†*Trachodon**Corythosaurus*†*Thescelosaurus*†*Monoclonius**Stegosaurus*†*Ankylosaurus*

MARINE REPTILES

Tylosaurus

† <i>Cryptocleidus</i>	† <i>Myrmecobius</i>
<i>Ichthyosaurus</i>	† <i>Phalangista</i>
SAURURÆ	† <i>Phascodomys</i>
<i>Archæopteryx</i>	* <i>Hypsiptymnodon</i>
ODONTORNITHES	* <i>Macropus</i>
† <i>Hesperornis</i>	CARNIVORA
APTERYGIFORMES	† <i>Patriofelis</i>
* <i>Apteryx</i>	† <i>Hyænodon</i>
STRUTHIFORMES	† <i>Pachyæna</i>
* <i>Struthio</i>	* <i>Felis</i>
CASUARIFORMES	PRIMATES
† <i>Dinornis</i>	* <i>Lemur</i>
DIATRYMÆ	* <i>Homo</i>
<i>Diatryma</i>	PERISSODACTYLA
GALLIFORMES	* <i>Tapirus</i>
<i>Gallus</i>	* <i>Equus</i>
ANSERIFORMES	* <i>Rhinoceros</i>
<i>Cygnus</i>	† <i>Palæosyops</i>
<i>Anas</i>	† <i>Brontotherium</i>
COCCYGES	PROBOSCIDEA
† <i>Geococcyx</i>	† <i>Mastodon</i>
MONOTREMATA	* <i>Elephas</i>
* <i>Echidna</i>	AMBLYPODA
* <i>Ornithorhynchus</i>	<i>Pantolambda</i>
MARSUPIALIA	† <i>Coryphodon</i>
† <i>Didelphys</i>	† <i>Uintatherium</i>

In the recent forms marked * the femoro-pelvic muscles have been considered in their relations with the bony elements, partly by "autoptic examination" of alcoholic specimens, partly by study of the dissections figured in the literature. In the recent and fossil forms marked † the bony elements alone have been examined, but with special reference to the probable origin, insertion, and function of certain femoro-pelvic muscles. In the remaining genera listed, as well as in many others not listed, the bones were examined but revealed little or nothing that had not already been noted in other genera.

The various trochanters have been tentatively homologized by direct comparison of the different genera and these tentative homologies were, so far as possible, confirmed by reference to the musculature of these parts in recent reptiles.

A.—OSTEOLOGICAL EVIDENCE

The head of the femur in all recent reptiles and in the great majority of fossil reptiles occupies the whole proximal end of the femur. It is widely oval in section, is located directly on the top of the shaft, instead of being

set off to one side as in mammals and birds, and is not separated from the shaft by a neck. The whole head could be thrust into the acetabulum when the femur was directed outward, as in primitive sprawling types; but when the femur is directed forward the outer part of the head protrudes from the acetabulum.

The "medial trochanter" (internal trochanteric crest) of Permian reptiles (Pl. XLVIII) appears to have been shifted either down the shaft to give rise to the "fourth trochanter" or up the shaft, as in lizards and turtles, to give rise to the lesser trochanter. Von Huene (1911, pp. 55-56) has noted that the medial trochanter of Permian and Triassic reptiles is homologous with the fourth trochanter of later types and Professor Williston informs the writer that he came to the same conclusion, which was also reached independently by the writer.

The trochanteric eminence on the under side of the femur of crocodiles, alligators, phytosaurs, and *Erythrosuchus* (Fig. 11), has every appearance of homology, on the one hand, with the medial trochanter of Permian types and, on the other hand, with the "fourth trochanter" of *Plateosaurus*, *Sellosaurus*, Theropoda, Ornithischia, and the birds. Dollo (1883) contrasted the femora of *Iguanodon* and of birds, on the one hand, with that of the crocodile, on the other, concluding that the femoral musculature of *Iguanodon* was more bird-like than reptilian. He left the medial trochanter of the crocodile unnamed and undefined, but direct comparison of the crocodile femur with that of a mounted *Trachodon* skeleton strengthens this probable homology. In another direction, the crocodile trochanter compares closely with those of *Typothorax*, *Plateosaurus*, and *Sellosaurus*, and these connect surely with the theropod and sauropod types. Again, direct comparison of the femora of *Allosaurus* and *Brontosaurus* with each other and with *Trachodon* bears out the apparent homology of the fourth trochanter in all.

In the therapsid-mammal series perhaps the most primitive femur examined was that of *Ælurosaurus* (Pl. XLVIII). The general form of the femur is almost typically reptilian. The widely oval head occupies the whole proximal end of the curved shaft, as in crocodiles, lizards, and primitive Permian reptiles. The latero-superior margin of the femur, near the proximal end, is raised into a wide swelling, which is apparently homologous with the great trochanter. The slight emargination between the head and the great trochanter represents the neck of the femur of mammals. On the medial surface of the femur is a long ridge, possibly homologous with the pectineal line of mammals but not ending above in a definite tubercle.

In the deinocephalian *Moschops* (Pls. XLVII, XLVIII) the head is excessively prolonged outward into a thin articular ridge, called the "trochanteric ridge" by Watson but regarded by the writer as part of the head;

the great trochanter itself is apparently represented by a low swelling on the outer side of the shaft. There is little, if any, trace of the medial ridge and trochanter. In *Dicynodon* the condition is essentially similar to that in *Ælurosaurus* save that the medial ridge is short and shifted to the medial border of the femur, in the position of a lesser trochanter.

In *Cynognathus* (Pl. XLVIII) we have a distinct approach to the mammalian condition. The widely oval head is becoming separated by an incipient notch, or neck, from the much enlarged and protruding great tro-

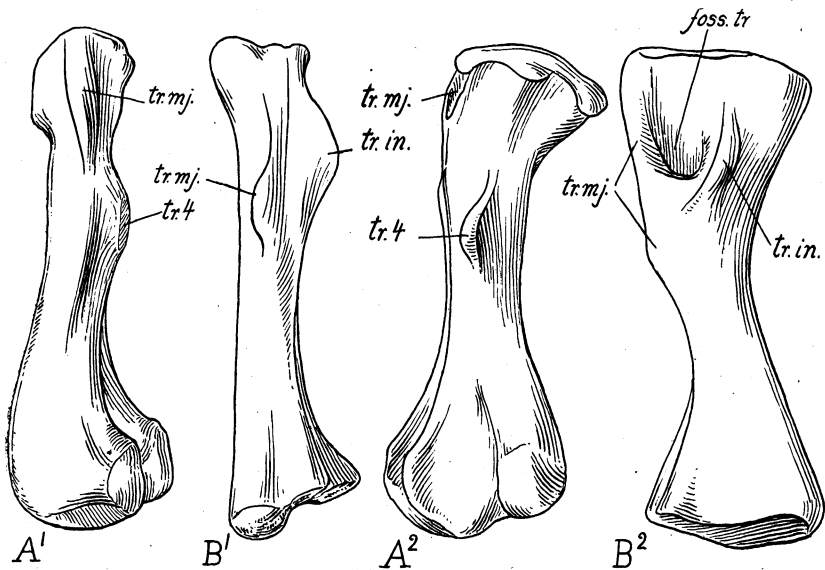


Fig. 11. Comparison of the femora of two early diapsid reptiles, indicating the probable homology of the "fourth trochanter" with the internal trochanter of primitive reptiles.

A¹. *Typhothorax coccinarum* Cope, Trias, New Mexico. Order Parasuchia or Pseudosuchia? Left femur, lateral aspect. Adapted from von Huene 1915.

Fourth trochanter clearly homologous with that of dinosaurs and with the internal trochanter of Crocodilia.

B¹. *Erythrosuchus africanus* Broom, Trias, South Africa. Order Pelycosimia. Left femur lateral aspect. Adapted from von Huene 1911.

Internal trochanter evidently homologous with that of Permian reptiles but in the way to assume the form and position of a fourth trochanter.

A². *Typhothorax coccinarum*. Left femur, posterior or caudal aspect. Adapted from von Huene 1915.

B². *Erythrosuchus africanus*. Left femur, posterior aspect. Adapted from von Huene 1911.

chanter. The medial ridge, near the medial border of the femur, is sharply defined and terminates above in a low eminence, which Seeley and Broom recognized as the homologue of the lesser trochanter of mammals. The third trochanter is not differentiated.

B.—EVIDENCE FROM THE MUSCULATURE

The evolution and morphology of the femoral trochanters are elucidated by a study of the functions of the muscle attachments and movements of the femur and of the pelvis. From Gadow's very complete descriptions of the limb muscles of recent reptiles the writer compiled lists of the origins, insertions, and directions of the muscles that move the femur in lizards, crocodilia, *Sphenodon*, and *Testudo*, and from this list, supplemented by examination of alcoholic specimens, it was found that the muscles could be conveniently grouped under four sets, with reference to the direction of movements of the femur (omitting the rolling or twisting movements), as follows:

1.—Muscles Tending to Draw the Femur Forward and Inward

a) *Quadratus lumborum*. In the alligator (Pl. XLIII) this muscle is attached on the upper third of the femur on the antero-dorsal surface. A powerful muscle connecting the axial and the appendicular systems.

b) *Pubi-ischio-femoralis internus* (Pl. XLIII). Running from the dorsal surface of the pubis and around its anterior borders, turning backward and inserted on or below the internal trochanter of the femur. For reasons which are discussed elsewhere in these papers, this group (pubi-ischio-femoralis internus) is believed to have given rise to the ilio-psoas + pectineus of mammals and is attached on or near or below the lesser trochanter (trochanter minor).

2.—Muscles Tending to Draw the Femur Chiefly Backward toward the Tail

a) *Caudi-femoralis* (Pl. XLIII). Attached to the back of the femur, either to the internal (fourth) trochanter or back of the external trochanter.

b) *Caudi-ilio-femoralis* (Pl. XLIII). Attached to the femur, either on the outer surface near the external trochanter (*Sphenodon*, Crocodilia) or on the posterior surface (Sauria), or on both trochanters and on the fossa trochanterica (Chelonia).

c) *Pubi-ischio-femoralis posterior* (Pls. XLIII, XLVI). Arises chiefly from the posterior region of the ischium and is inserted on the posterior region of the ischium and is inserted on the posterior surface of the femur, either in the trochanteric fossa (Sauria), or on the external trochanter (*Sphenodon*), or on the posterior surface of the femur from the internal

trochanter down nearly to the condyles (Crocodilia). This muscle is probably homologous with the so-called "ischiofemoralis" of birds,¹ which is inserted on the crest *above* the fourth trochanter. It is also probably homologous with the obturator internus and associated muscles of mammals, which are inserted in or near the digital fossa.

3.—Muscles Tending to Draw the Femur Inward or Inward and Backward Toward the Pelvis

a) *Pubi-ischio-femoralis externus* (Pl. XLIII, XLV, XLVI). Arising from the outer surface of the pubi-ischiadic plate and inserted in the region of the trochanteric fossa and often on the internal trochanter. This muscle is probably homologous with the obturator externus of mammals, which is inserted in the trochanteric, or digital, fossa.

b) *Ischio-femoralis* (Gadow) (Pls. XLIII, XLVI). Inserts on the posteromedial surface of the femur below the trochanter. Probably homologous with the adductor muscles of mammals.

4.—Muscles Tending to Extend and Abduct the Femur (i. e. to Draw it Upward toward the Ilium)

a) *Ilio-tibialis* I (= *Glutæus maximus*). Pl. XLIII.

b) *Ilio-tibialis* II (= *Sartorius*). Pl. XLIII.

c) *Ilio-femoralis* (= *Glutæus medius* + *minimus*). Pl. XLIII. Inserted on the external trochanter or on the outer border of femur.

d) *Ambiens* (= *Rectus femoris*). Pls. XLIII, XLVII.

CONCLUSIONS

From the foregoing analysis we may define the trochanteric fossa and extend and revise the definitions of the several trochanters given by Dollo.

Trochanteric Fossa (Pl. XLVIII)

(= Digital fossa of mammals)

A more or less V-shaped area on the medial surface of the femur, usually near the proximal end. Bounded originally chiefly by the external and internal trochanteric crests. Originally this fossa may have given insertion to the following muscles:

(a) *Pubi-ischio-femoralis externus* (= obturator externus). Partly on internal trochanter.

(b) *Pubi-ischio-femoralis posterior* (= obturator internus, gemelli + quadratus femoris).

¹ See table on p. 505.

(c) *Caudi-femoralis*. May have been attached around the borders of the trochanteric fossa, extending below it on the medial surface of the shaft.

(d) *Caudi-ilio-femoralis*. Perhaps more on outer margin of fossa.

In mammals groups *a* and *b* are still inserted in the trochanteric (digital) fossa; *c* and *d* are no longer associated with it.

External Trochanter (Pl. XLVIII)

(= Trochanter major, great trochanter, of mammals)

Arising primarily from the outer border of the shaft towards the proximal end, giving insertion on its outer border to the *ilio-femoralis*, posteriorly to part of the *caudi-ilio-femoralis*. On its posterior surface the region of the great trochanter sometimes gives insertion also to the *caudi-femoralis*. The great trochanter in most reptiles (including the Sauropoda) remains on the outer side of the shaft more or less near the proximal end. The outer portion of the head itself has sometimes been wrongly called "great trochanter," especially in the femur of Sauropoda.¹

Internal Trochanter (Pl. XLVIII)

(= Trochanter minor, tr. medialis, lesser trochanter)

Giving insertion especially to the *pubi-ischio-femoralis internus*, which gives rise to the iliopsoas + pectineus, which tends to pull the femur forward. Other muscles more or less closely associated with the internal trochanter are the *pubi-ischio-femoralis externus* (= obturator externus), and the adductors (*pubi-ischio-femoralis posterior*).

Fourth Trochanter (Pl. XLVIII and Fig. 11)

(Of birds, dinosaurs, phytosaurs, etc.)

Represents the middle and lower parts of the primitive internal trochanteric crest. Present in crocodilia, phytosaurs, etc., dinosaurs and birds.

Together with the crest above it, it gives insertion especially to

caudi-femoralis (part I)

ischio-femoralis (= adductors)

pubi-ischio-femoralis posterior (= obturator internus).

The lesser trochanter of mammals and the fourth trochanter of birds and dinosaurs are therefore divergent derivatives of the internal trochanter

¹ The writer inclines to the opinion that in the ornithischian dinosaurs the proximal surface of the so-called great trochanter was covered by a bursa, as is the similar smooth surface above the great trochanter in the Ostrich (Garrod and F. Darwin, 1872); and that the gluteal muscles were attached on the outer side of the great trochanter and not upon its top.

of primitive reptiles. The lesser trochanter of mammals, representing the upper or proximal part of the primitive trochanteric crest, points forward and is associated especially with the pubi-ischio-femoralis internus (= ilio-psoas + pectineus). The fourth trochanter, derived from the distal part of the primitive trochanteric crest, points backward and is associated especially with the ischio-femoralis, pubi-ischio-femoralis posterior and caudi-femoralis (part I).

Third Trochanter (Pl. XLVIII, *Pachyaena*)
(Of primitive placental mammals)

Apparently represents a new attachment of the ilio-tibialis, part II, (= glutæus maximus) which originally ran to the tibia, as it does in reptiles and monotremes.

The following table summarizes the relations of the several trochanters to the muscles and the probable homologies of the latter.

	SPHENODON	ALLIGATOR	MONOTREME	PLACENTAL
Muscle	Ilio-femoralis	Ilio-fem.	{ Gluteus minimus Gluteus medius	{ Gluteus minimus Gluteus medius
Insertion	Latero-sup. border of femur	The same	Trochanter major	Trochanter major
Muscle	Ilio-tibialis	Ilio-tibialis ext.	Gluteus maximus	{ Gluteus max. Agitator caudæ
Insertion	Head of tibia	On tibia	Tibia and fibula	3rd trochanter (glut. max.)
Muscle	Pubi-ischio-fem. int.	The same	{ Pectineus (c) Iliacus (b) Psoas major (a)	Pectineus Iliacus Psoas major
Insertion	On medial trochanter	Near and on medial trochanter	Insertion: (a) on troch. minor (b) near " (c) below "	The same

LITERATURE REFERRED TO IN PARTS I-IV

- CARLSSON, ALBERTINA. 1915. Zur Morphologie des *Hypsiprymnodon moschatus*. Kongl. Svensk. Vet.-Akad. Handlingar, LII, No. 6, pp. 1-48, Pls. I, II.
- COUES, ELLIOTT. 1868. On the myology of the *Ornithorhynchus*. Proc. Essex Inst. VI [volume issued March, 1870], pp. 127-173.
- CUNNINGHAM, D. J. 1882. The relation of nerve-supply to muscle-homology. Jour. Anat. and Physiol., XVI, pp. 1-9.
1903. Text-book of anatomy. New York.
- CUVIER, G. AND LAURILLARD, C.-L. 1849. Anatomie Comparée. Recueil de Planches de Myologie. 338 plates in folio. Paris.
- DOLLO, L. 1883. Note sur la Présence chez les Oiseaux du "Troisième Trochanter" des Dinosauriens et sur la Fonction de Celui-ci. Bull. Mus. Roy. Hist. Nat. Belg., II, pp. 13-19, Pl. I.
- FEWKES, J. W. 1877. Contributions to the myology of *Tachyglossus hystrix*, *Echidna hystrix* (Auct.). Bull. Essex Inst., IX [volume issued 1878], pp. 111-137, 2 Pls.
- FÜRBRINGER, MAX. 1873. Zur vergleichenden Anatomie der Schultermuskeln. Jen. Zeit. Naturwiss., VII, pp. 237-320, Pls. XIX-XVIII.
1900. Zur vergleichenden Anatomie des Brustschulterapparates und der Schultermuskeln, IV. Teil. Nachträge zu Kapitel IV. Neuere Litteratur und neue eigene Untersuchungen, betreffend die Lacertilien, Rhynchocephalier und Crocodilier, sowie die anderen Reptilien. Jen. Zeit. Naturwiss., XXXIV, pp. 215-718, figs. 103-173 and Pls. XIII-XVII.
- GADOW, H. 1880. Zur Vergleichenden Anatomie der Muskulatur des Beckens und der hinteren Gliedmasse der Ratiten. 4to Jena, pp. 1-56, 5 Pls.
1882. Observations in comparative myology. Sec. 1. On the naming of muscles. Journ. Anat. and Physiol., XVI, pp. 493-514.
- 1882a. Untersuchungen über die Bauchmuskeln der Krokodile, Eidechsen und Schildkroten. Morph. Jahrb., VII, pp. 57-100, 1 Pl.
- 1882b. Beiträge zur Myologie der hinteren Extremität der Reptilien. Morph. Jahrb., VII, pp. 329-466, 5 Pls.
- GADOW, HANS AND SELENKA, EMIL. 1891. Dr. H. G. Bronn's Klassen und Ordnungen des Thier-Reichs wissenschaftlich dargestellt in Wort und Bild. Sechster Band. Vierte Abtheilung Vögel. I Anatomischer Theil. pp. 1-1008, Pls. I-LIX.
- GARROD, A. H. AND DARWIN, FRANK. 1872. Notes on an Ostrich lately living in the Society's Collection. Proc. Zool. Soc. Mar V, pp. 356-363.
- [Records presence of a small osseous plate attached to the antero-ventral border of the pubis.]
- GREGORY, W. K. 1912. Notes on the principles of quadrupedal locomotion and on the mechanism of the limbs in hoofed animals. Ann. N. Y. Acad. Sci., XXII, pp. 267-294.
1915. Present status of the problem of the origin of the Tetrapoda, with special reference to the skull and paired limbs. Ann. N. Y. Acad. Sci., XXVI, pp. 317-383, Pl. IV.
- HAUGHTON, SAMUEL. 1865. On the muscular anatomy of the leg of the crocodile. Ann. and Mag. Nat. Hist., (3) XVI, pp. 326-331, Pl. XVI.

1867. Notes on animal mechanics. VI. On the muscular anatomy of the crocodile. *Proc. Roy. Irish Acad.*, IX [issued 1864-1866], pp. 268-277, 2 figs. in text.
1868. On the muscular anatomy of the alligator. *Ann. and Mag. Nat. Hist.*, (4) I, pp. 282-292, Pl. x.
- HUENE, FRIEDRICH VON. 1907-1908. Die Dinosaurier der Europäischen Triasformation mit Berücksichtigung der Aussereuropäischen Vorkommnisse. *Geol. u. Pal. Abh. (Koken) Suppl. I.* [Osteology of Triassic theropods, restoration of the myology of *Plateosaurus*.]
1911. Beiträge zur Kenntnis und Beurteilung der Parasuchien. *Geol. u. Pal. Abhandl. herausg. von E. Koken, N. F.*, X, Heft 1 [pp. 55-56, homology of medial trochanter].
- 1911a. Über *Erythrosuchus* Vertreter der Neuen Reptil-Ordnung *Pelycosimia*. *Idem*.
1913. Beobachtungen über die Bewegungsart der Extremitäten bei Krokodilen. *Biol. Centralblatt*, XXXIII, Nr. 8, Aug., pp. 468-472.
- HUMPHRY, C. M. 1872. On the Disposition of Muscles in Vertebrate Animals. *Jour. Anat. and Physiol.*, VI, pp. 293-376, Pls. XIII-XVI.
- KEITH, ARTHUR. 1913. *Human Embryology and Morphology*. 3rd Edition, 80. London. [Morphology of the pelvic floor, pp. 396-398.]
- MATTHEW, W. D. AND GRANGER, W. Unpublished drawings: reconstructions of the myology of the fore limb of *Brontosaurus*, comparison with *Alligator*.
- McKAY, W. J. STEWART. 1894. The morphology of the muscles of the shoulder-girdle in monotremes. *Proc. Linn. Soc. N. S. Wales*, (2) IX, part 2, Dec. [volume issued 1895], pp. 263-360, Pls. XX-XXIII. [Extensive review of literature critically treated.]
- MIVART, ST. GEORGE. 1865-1866. On some points in the anatomy of *Echidna, hystrix*. *Trans. Linn. Soc. London*, XXV [volume issued 1866], pp. 379-403, 2 Pls.
1867. Notes on the myology of *Iguana tuberculata*. *Proc. Zool. Soc. London*, June 27, pp. 766-797, 18 text figs.
- OSAWA, GAKUTARO. 1898. Beiträge zur Anatomie der *Hatteria punctata*. *Archiv. für Mikros. Anat. u. Entwickl.*, LI, pp. 481-691, 53 text figs.
- PARSONS, F. G. 1896. On the anatomy of *Petrogale xanthopus*, compared with that of other kangaroos. *Proc. Zool. Soc. London*, pp. 683-714.
1911. Muscular System (*Anatomy*). *Encyclopædia Britannica*, Eleventh Edition, XIX, pp. 51-59.
- REIGHARD, JACOB AND JENNINGS, H. S. 1902. *Anatomy of the cat*. 2nd Ed. xx+498 pp., 173 text figs. Henry Holt & Co., New York.
- ROLLESTON, GEORGE. 1869. On the homologies of certain muscles connected with the shoulder-joint. *Trans. Linn. Soc. London*, XXVI, pp. 609-629.
- SABATIER, A. 1879. Comparaison des ceintures thoracique et pelvienne dans la série des Vertébrés. *Mem. de l'Acad. d'Sci. et Lettr. de Montpellier (Sec. des Sci.)*, IX, pp. 337-709, 8 Pls.
- WATSON, D. M. S. 1917. The Evolution of the Tetrapod Shoulder Girdle and Fore-limb. *Journal of Anatomy*, LII, part 1, pp. 1-63.
- WESTLING, CHARLOTTE. 1884. Beiträge zur Kenntniss der peripherischen Nervensystems [in (1) *Pithecius satyrus*, (2) *Ornithorhynchus paradoxus*]. *Bihang k. Svenska Vet.-Akad. Handlingar*, IX, No. 8, pp. 1-48, 3 Pls.

1889. Anatomische Untersuchungen über Echidna. Idem, XV, Afd. 4, No. 3, pp. 1-71, 6 Pls.
- WEISSE, FANEUIL D. 1899. Practical Human Anatomy. 4th Edition, "Atlas" form. New York. 222 plates.
- WILDER, H. H. 1909. History of the human body. New York.
- WILLISTON, S. W. 1911. American Permian vertebrates. Chicago. [Osteology of *Varanosaurus*, *Casea*, *Seymouria*].
- WILSON, J. T. AND MCKAY, W. J. STEWART. 1893. On the homologies of the borders and surfaces of the scapula in monotremes. Proc. Linn. Soc. N. S. Wales, (2) VIII, part 3, Oct. [volume issued 1894], pp. 377-388, Pl. xxi.
- WINDLE, B. G. AND PARSONS, F. G. 1897. On the myology of the terrestrial Carnivora. Part I. Proc. Zool. Soc. London, pp. 370-409.
1898. Part I, idem, pp. 152-186.
1901. On the muscles of the Ungulata. Part I, idem, pp. 656-704.
1904. Part II, idem, pp. 261-298.
- WOOD, JOHN. 1867. On human muscular variations and their relation to comparative anatomy. Journ. Anat. and Physiol., I, pp. 44-59, figs. 1-6.

PART V.—A RECONSTRUCTION OF THE SKELETON OF *CYNOGNATHUS*

BY W. K. GREGORY AND C. L. CAMP

The partial skeleton of *Cynognathus crateronotus* described by Seeley (1895) included, besides the almost perfect skull and mandible, a nearly complete backbone (except for the tail, which was represented by only a few of the proximal caudals), a well preserved scapulocoracoid, the greater part of the pelvis, and the proximal parts of the humerus and femur. Casts of these parts, supplied by the British Museum, have been used in the present studies, together with fragments of the girdles and limb bones of *Cynognathus* in the Broom collection of this Museum.

The subordinal characters of the missing parts of the limbs were probably not very dissimilar to those of "*Microgomphodon*" *eumerus* (Fig. 12) as described and figured by Seeley. According to Watson this skeleton probably represents a small cynognathid, and the very peculiar character

Fig. 12. *Microgomphodon eumerus* Seeley (small cynognathid, Watson), Trias, South Africa. Natural size. After Seeley 1895.

Part of skeleton, showing ventral aspect of hinder part of vertebral column, pelvis, and hind limb.

E. Posterior part of the dorsal region showing the eleventh (?), twelfth (?) and thirteenth (?) ribs (cf. Fig. 13, A).

C. Lower dorsal, lumbar and sacral regions, with the pelvis and left hind limb.

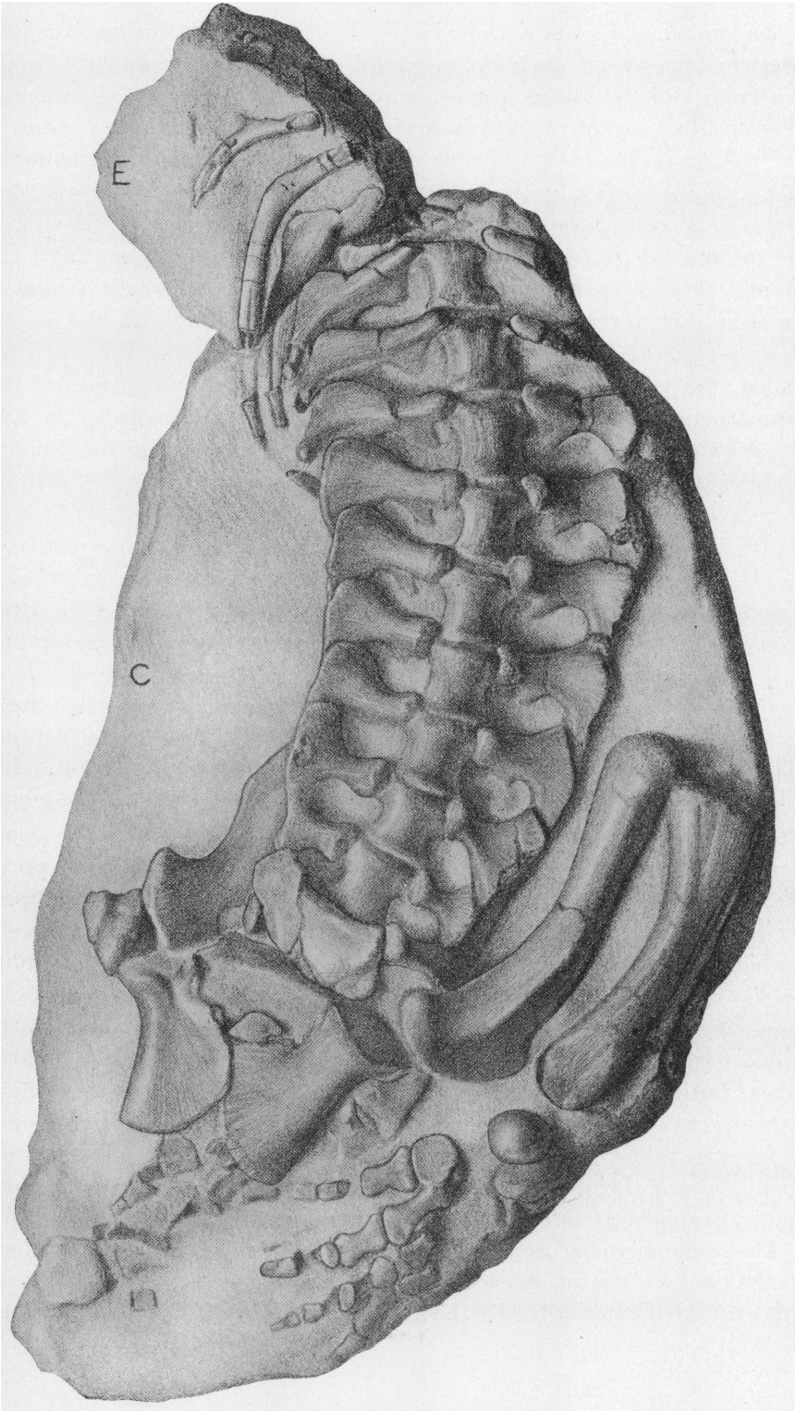


Fig. 12.

of the lumbar and lower dorsal ribs which it shares with *Cynognathus* indicates that the rest of the skeleton must be fundamentally similar. As the greater part of the manus and pes is preserved in this animal, it probably gives us a fair idea of the character of the feet of *Cynognathus*, except as to size and proportions. The femur of *Tribolodon* Seeley and the femur of *Diademodon* described by Broom doubtless supply a general idea of the form of the distal end of the femur of *Cynognathus*. The region of the clavicle and interclavicle of *Cynognathus* has been described by Broom (1909) and the missing upper part of the ilium was doubtless fundamentally similar to the same part in other therapsids, especially *Diademodon*. In the accompanying reconstruction (Plate XXXIX) the parts actually preserved are shaded, the missing parts are dotted. The most doubtful points of this reconstruction are the precise lengths of the limbs and the size of the feet. The drawings were made by Mrs. Elizabeth M. Fulda under the direction of the authors.

Seeley (1895, p. 97) gives the vertebral formula as C 6 (?), D 18, L 5, S 3, Cd ?, but a careful study of the casts indicates that it was very probably C 7, D 17, L 4, S 4, Cd ?. What Seeley calls the first cervical vertebra is evidently the axis with the attached pleurocentrum (odontoid) of the atlas, exactly as in *Dimetrodon*; the arch of the atlas and the pro-atlas are not preserved, but they have been described by Broom (1903) in another cynodont, *Gomphognathus kannemeyeri*. The atlanto-axis complex is essentially similar to that of monotremes and marsupials save for the retention of the pro-atlas. The first dorsal (Fig. 13, A) has the transverse process on a higher level than that of the last cervical as observed by Seeley. The ribs articulate with the transverse processes and between the vertebræ. The upper dorsal ribs were probably long and slender, as in *Microgomphodon eumerus*. The thirteenth to seventeenth ribs, inclusive, shorten up rapidly and project widely; near the proximal end they bear remarkable expansions, each of which overlaps the succeeding rib and is received into a concavity on its anterior border, so that there is, as it were, a set of secondary zygapophyses connecting these ribs. This remarkable specialization culminates in the lumbar series, in which the ribs lose the free portion of the shaft and end in widely flaring interlocking ends. This arrangement gives great strength to the lower dorsal and lumbar region; its possible adaptational significance is suggested below. There were very probably twenty-eight presacral vertebræ, the series being practically complete as to number. The same number of presacral vertebræ is recorded by Broom (1913) in the Dromosauria.

The vertebra which we identify as the first sacral (Fig. 13, A) is much like the lumbar, having on each side a distally expanded rib, which receives in its excavated anterior border the posterior blade of the rib in front of it;

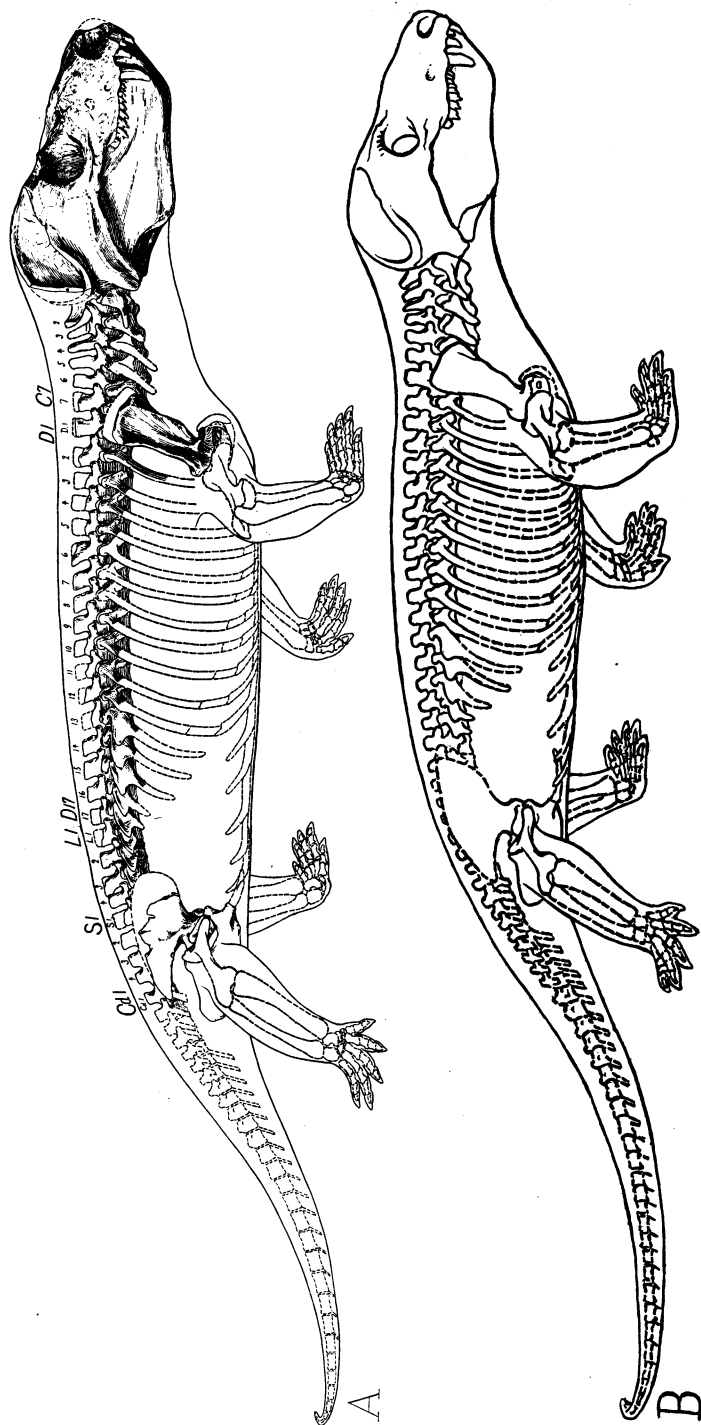


Fig. 13. Provisional reconstruction of *Cynognathus crateronotus* Seeley. About one-twelfth natural size.
 A. First reconstruction. Fully shaded parts based on casts of the original skeleton. Dotted parts restored more or less conjecturally, chiefly from *Microgomphodon eumerus* Seeley, a nearly related animal. In this reconstruction the ilium is probably placed too low down on the sacral vertebra.
 B. Second reconstruction with corrected position of pelvis.

but the first sacral rib bears also on its posterior border a flattened expansion to which was probably attached the anterior extension of the ilium. Another reason for regarding this vertebra as the first functional sacral is that when the pelvis is placed below the true sacrals the anterior extension of the ilium comes opposite the first functional sacral rib as it does also in "*Microgomphodon*." (In our first restoration, Fig. 13, A, the ilium is probably placed too low with reference to the vertebræ). Thus the first functional sacral vertebra of *Cynognathus* may well represent a partly modified lumbar. The true sacrals are three smaller vertebræ which have their ribs connecting distally. According to Seeley the four caudal vertebræ following the last sacral are preserved and indicate that the tail was small.

A study of the scapulocoracoid in comparison with those of various reptiles and of monotremes (see pp. 510-512 above) indicates that the scapula was not turned backward over the ribs, as in typical mammals and certain reptiles, but that it was even inclined forward,¹ as in monotremes, and that the opposite scapulæ diverged widely.

The general form of the pectoral girdle and of the humerus approached the Monotreme type, with certain exceptions, so that probably the posture of the fore limbs was more like that of Monotremes than like that of primitive Placentals.

The scapula of the cynodonts (Pl. XL) is unique among reptiles in having the anterior border sharply everted, this foreshadowing the spina scapulæ of monotremes and other mammals, and in having an incipient prespinous fossa, beginning at the upper front corner of the scapula. The significance of this arrangement with reference to the muscular anatomy has been discussed above (p. 511). The reflected border runs down into a prominent acromial process forming the articular projection for the clavicle.

The humerus, which is restored from *Gomphognathus*, differs from the marsupial type especially in having the head flatter and much less differentiated from the shaft. It has a stout delto-pectoral crest (processus lateralis) and widely expanded distal end, as in other primitive reptiles and mammals.

The radius and ulna are partly known in *Microgomphodon*. The radius must have been markedly shorter than the tibia. The manus was probably short and spreading as in *Microgomphodon* and *Ælurosuchus*; not improbably there were ten elements in the carpus, including two free centralia. The fourth digit was the longest and digit III was nearly as long. The phalangea formula was very probably 2.3.3.3.3, as it is in the hind foot of "*Microgomphodon*."

In correlation with the wide expansion of the gluteal surface of the ilium,

¹ Watson comes to the same conclusion (Journal of Anatomy, Oct. 1917).

suggesting a corresponding development of the deep gluteal muscles, the femur has developed a very large great trochanter. The great size of the acetabulum is correlated with the widely oval head of the femur, which could be freely twisted in various directions. The projection of the iliac margin of the acetabulum and the emphasis of the cotyloid notch enable the head of the femur to be placed in such a way that the knees could be drawn forward more than in the primitive Permian reptiles. When resting or moving slowly, however, the knees were turned more outward. The pelvis below the acetabulum is more extended behind it than in front; this tendency is greatly emphasized in primitive mammals, birds and ornithischian dinosaurs, which all turn the femora forward, so that it again seems probable that, in running, *Cynognathus* turned the femora further forward than did the primitive Permian reptiles.

The lesser trochanter of the femur (Pl. XLVIII) is also approaching the mammalian position near the proximal end of the shaft, although more in the middle of the medial surface of the femur than in mammals. The tarsus is not well known even in "*Microgomphodon*." The foot of "*Microgomphodon*" is short and spreading.

The animal as a whole, which is restored in a slow-moving pose, has an extremely large head, short neck, short sprawling limbs, stout backbone, and fairly short tail. It parallels both the crocodilian and primitive mammalian types in its predatory habitus (including the carnivorous dentition, the secondary palate, and the marked differentiation of dorsal and lumbar regions). The sharp differentiation of the lumbar from the dorsal region probably indicates that the quadratus lumborum had begun to lose its metameric character — Gadow shows that it is the serial homologue of the intercostal muscles — and may indicate that this muscle was attached to the femur, as in alligators, while the pubi-ischio-femoralis internus may well have begun to differentiate into the iliopsoas and pectineus. The peculiar characters of the lower dorsal and lumbar ribs are possibly connected with the extremely large size and powerful musculature of the head which might require an equally strong development of the axial musculature, especially of the longus colli, recti capiti antici, and quadratus lumborum on the ventral side of the column, and of the complexus, spinalis, longissimus dorsi, and ilio-costalis on the dorsal side. The iliocostalis especially, was probably very large and to its great development the shortening of the lumbar ribs may perhaps be attributed. The sharp differentiation of the dorsal and lumbar region may also indicate that the muscular complex forming the diaphragm had already reached the lower dorsal region in its backward migration from the pericardium.¹ In any event, *Cynognathus* and *Micro-*

¹ Cf. Keith, A. 1913. *Human embryology and morphology*, pp. 337-340.

gomphodon retained true ribs, although of peculiar form, in the lumbar region, while in the mammals these have been replaced by outgrowths from the centra.

In general, the cynodonts foreshadowed the mammalian grade in a long list of characters of the skull and lower jaw and in the differentiation of the dorsal and lumbar regions, but, on the other hand, they retained the reptilian heritage in many characters of their limbs and girdles. They were doubtless normally sluggish animals, with rather small reptilian brains and imperfect heat-conserving and heat-producing adaptations, capable perhaps of stealthy pursuit and a sudden rush (straightening the hind limb somewhat in this movement), but not to be compared in speed or endurance with predatory cursorial mammals.

LITERATURE REFERRED TO IN PART V

- BROOM, R. 1903. On the axis, atlas, and proatlas in the higher theriodonts. *Proc. Zool. Soc. London*, Feb. 17, pp. 177-180, 1 Pl.
1905. On some points in the anatomy of the theriodont reptile *Diademodon*. *Idem*, June 1, pp. 96-102, 1 Pl. [Femur, pelvis and lumbar vertebræ.]
1906. On a new cynodont reptile (*Eluerosuchus browni*). *Trans. So. Afr. Philos. Soc.*, XVI, part 4, Dec., pp. 376-378, 1 Pl. [Manus. Pl. x, figs. 1, 7.]
1909. On the shoulder-girdle of *Cynognathus*. *Ann. So. Afr. Mus.*, (4) VI, part 3, April 28, pp. 283-284.
1913. Croonian Lecture: On the origin of mammals. *Philos. Trans. Roy. Soc. London*, (B) CCVI, June 5 [separate issued Oct. 31, 1914], pp. 1-48, 7 Pls.
- SEELEY, H. G. (1895). Researches on the structure, organization, and classification of the fossil Reptilia. Part IX, Section 4.—On the Gomphodontia. *Philos. Trans. Roy. Soc. London*, (B) CLXXXVI, pp. 1-57, Pls. i, ii. [Humerus of *Gomphognathus*, p. 29; skeleton of *Microgomphodon eumerus*, pp. 35-48, Pl. i, figs. 6, 7, 8.]
- (1895). *Idem*. Part IX, Section 5.—On the skeleton in new Cynodontia from the Karroo Rocks. *Idem*, pp. 59-148. [Postcranial skeleton of *Cynognathus*, pp. 91-121; femur and fibula of *Tribolodon*, pp. 146-148.]
- (1895). *Idem*. Part IX, Section 6.—Associated remains of two small skeletons from Klipfontein, Fraserburg. *Idem*, pp. 149-162. [Fore limb of *Herpetochirus*, p. 158.]
- WATSON, D. M. S. 1914. Notes on some carnivorous therapsids. *Proc. Zool. Soc. London*, pp. 1021-1038. [Skeleton referred by Seeley to *Microgomphodon oligocynus* really a cynognathid.]
1917. The Evolution of the Tetrapod Shoulder Girdle and Fore-limb. *Journal of Anatomy*, LII, part 1, pp. 1-63. [Cynodontia, pp. 22-30.]
- WILSON, J. T. AND MCKAY, W. J. S. 1893. On the homologies of the borders and surfaces of the scapula in monotremes. *Proc. Linn. Soc. N. S. Wales*, (2) VIII, part 3, Oct. [issued 1894], pp. 377-388, Pl. xxi.

PART VI.—SECOND NOTE ON THE EVOLUTION OF THE CORACOID ELEMENTS IN REPTILES AND MAMMALS

BY W. K. GREGORY

The present note is a sequel to the brief discussion of the long-standing coracoid problem published in 1915.¹ At that time the facts recorded by Parker, Howes, Lydekker, Broom, Williston, and others, led the writer to the conclusion that three distinct parts of the coracoid complex are involved in the problem of the homologies of the "coracoids" of reptiles and mammals and not two, as assumed by previous investigators:

(a) the epicoracoid, of *Sphenodon*, lizards, and monotremes, a sheet of bone lying immediately above the clavicles and never reaching the glenoid surface;

(b) the true coracoid, or so-called precoracoid, lying behind the clavicles, originally pierced by the coracoid foramen, forming at least the front part of the glenoid, often articulating with the sternum; and

(c) the metacoracoid, of Permian reptiles, originally forming the back part of the glenoid region, lost in later reptiles (Williston) and in mammals, except when preserved as a vestigial element (Howes).

This view was in opposition to that of Broom (1912) who held that there were only two elements involved, of which the posterior element (metacoracoid) gave rise to the coracoid of mammals, while the anterior one (precursor) gave rise to that of birds and of those reptiles which have a single coracoid.² Dr. Broom homologized the epicoracoid and coracoid elements of monotremes with the "precursor" and "metacoracoid," respectively, of South African mammal-like reptiles, a comparison which has at first sight a great appearance of truth for it is difficult to realize that the monotremes have lost the metacoracoid and, as will be shown below, that the therapsids and other Permian reptiles probably had a thin epicoracoid in front of the precursor. We must also assume, if the coracoid of monotremes represents the "precursor" of therapsids, that the precursor foramen and its nerve, which are such constant features in reptiles, have been lost in mammals. But, as this foramen is absent in the coracoid of many birds, which is plainly homologous with the "precursor," its absence in monotremes does not constitute a serious objection to the supposed

¹ Ann. N. Y. Acad. Sci., XXVI, pp. 369-375.

² Watson also, in a paper which was received too late for extended notice here (Journal of Anatomy, October, 1917), holds that the metacoracoid of Permian reptiles gave rise to the true coracoid of mammals.

homology of the monotreme coracoid with the precoracoid of Permian reptiles.

Professor Williston's discoveries and observations on American Permian reptiles have afforded very strong evidence amounting almost to a demonstration that the "single coracoid" of lizards, *Sphenodon*, and other typical reptiles represents not a fusion of the pre- and metacoracoids but the precoracoid alone.

The studies of the junior author have revealed the fact (hitherto scattered in the literature of myology) that the single coracoid of *Sphenodon* (Pl. XLIX), homologous with the precoracoid and pierced by the precoracoid foramen, gives origin on its ventral surface to a group of muscles comprising the biceps and the three branches of the coracobrachialis, which group appears to be precisely homologous with a similar group of muscles carried by the ventral surface of the coracoid of monotremes. The dorsal surface of the coracoid in *Sphenodon* gives origin to the whole of the subcoracohumeralis. In monotremes an homologous muscle (subcoracoideus) likewise arises in part from the dorsal surface of the coracoid but, as it is very large, it also extends over the dorsal surface of the epicoracoid. The arrangement of the muscles, therefore, appears to confirm the homology of the coracoid (= precoracoid) of *Sphenodon* with the coracoid of monotremes.¹

Comparison of the monotreme shoulder-girdle with that of the alligator (Pl. L) adds further evidence in the same direction; for not only is the single perforated coracoid of the alligator essentially like the true coracoid of *Ornithorhynchus* in form and position but it also gives origin to the biceps, coracobrachialis, and supracoracoid muscles, the latter likewise extending on to the epicoracoid membrane.

The epicoracoid of *Sphenodon* is widely excluded from the glenoid, exactly like the epicoracoid of monotremes; it also has identical relations with the clavicle and interclavicle. The epicoracoid of both *Sphenodon* and monotremes carries the anterior part of the supracoracoid muscle, or epicoracohumeralis, on its ventral surface.

The whole complex of relations of the epicoracoid and coracoid of monotremes to each other and to the scapula, clavicle, and interclavicle is practically identical with the relations of the same set of elements in lizards and *Sphenodon* as shown in the accompanying figures. But, if the epicoracoid of monotremes be not homologous with that of *Sphenodon* and lizards, we have to imagine a bewildering set of substitutions, not only among these elements but also of the muscles they carry, for which we have but little

¹ It is only fair to state, however, that Watson (*op. cit.*) cites the position of these muscles in *Sphenodon* and the Monotremes in support of the opposite conclusion.

evidence. The epicoracoid, which must have bordered the precoracoid of the ancestral Permian types as a thin unossified sheet, would have to disappear in the mammalian line and the precoracoid would have to take its place, while at the same time the muscles would have to shift in such a way that the biceps-coracobrachialis group would finally lodge upon the metacoracoid in mammals and upon the precoracoid in reptiles. Such assumptions seem to be more difficult to accept without direct evidence than the inference that the ancestors of the mammals, as well as other progressive reptiles and birds, tended to lose the metacoracoid. And, when we realize that in very many parts of their anatomy the monotremes have advanced far beyond the mammal-like reptiles and that even in their coracoids they bear only a general resemblance to them, it becomes less incredible that they should have progressed also in the matter of losing the metacoracoid, even while retaining the ancient contact of the precoracoid (= true coracoid) with the sternum.

That the Permian therapsid reptiles did have a membranous epicoracoid in front of the "precoracoid" is indicated by the fact that in assembling the parts of the shoulder-girdle of *Moschops* it was found that there was a space between the clavicles, interclavicles, and precoracoids which must have been filled by the epicoracoids, as in *Sphenodon* and lizards. In *Eryops* also the anterior edges of the coracoids clearly indicate the presence of a membranous epicoracoid.

It is probable that in the therapsid-mammal group the metacoracoid persisted longer than in some of the more typical reptilian phyla. In the Triassic cynodont *Cynognathus* (Fig. 14) it is still very well developed and, owing to the total lack of mammalian skeletons from the Jurassic and Cretaceous, its reduction and disappearance during those periods will perhaps never receive direct palæontological proof. The metacoracoid was perhaps only one of many elements of the endoskeleton of primitive reptiles which, as it were, lacked vitality and were gradually eliminated in all later phyla.

The selection of the precoracoid rather than the metacoracoid as the survivor of the two original elements is possibly connected with the fact that in all progressive phyla there was a tendency to draw the elbows in toward the body, which caused the chief pressure from the head of the humerus to be exerted on the anterior, or precoracoid, part of the glenoid fossa. In this way the articular surface was gradually shifted forward. Meanwhile the head of the humerus and the glenoid cavity were enlarging and tending to crowd the metacoracoid away from its contact with the scapula, so that even in *Moschops* the connection between the metacoracoid and the scapula was small and weak (Fig. 15). The true coracoid, on the other hand, was broadly braced by the scapula and by the epicoracoid, so

that when the connection with the sternum was broken, through the reflection of the scapula, the coracoid adhered to the scapula.

A fourth element in the coracoid complex which has given rise to much confusion is the "subcoracoid center" of placental mammals, which Howes, Lydekker, and others regarded as the last vestige of the metacoracoid. We have verified the occurrence of this element, which finally fuses with the scapula, in many orders of placental mammals but we were unable to find it

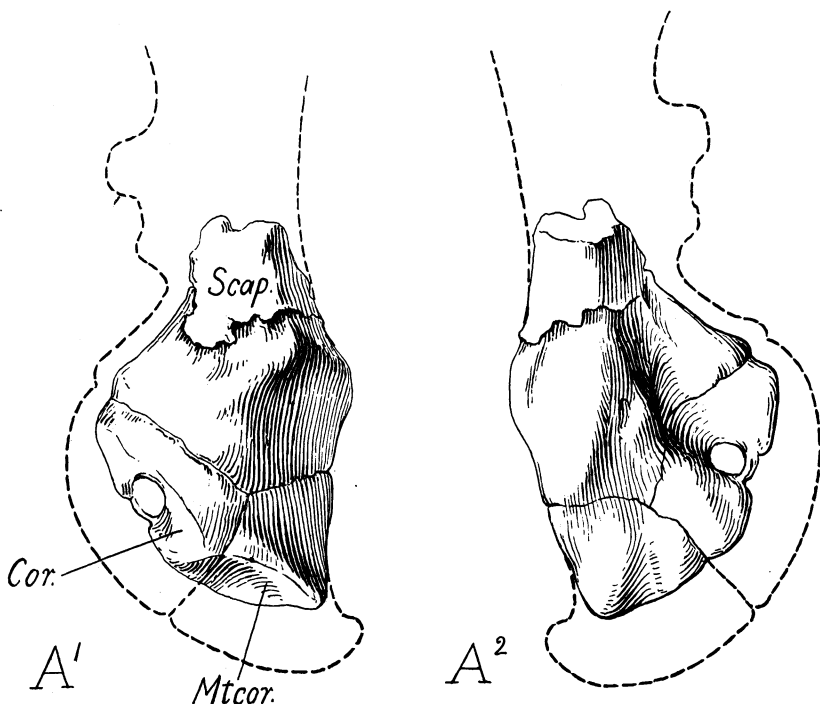


Fig. 14. Relations of the coracoid, metacoracoid and scapula in *Cynognathus* sp., Broom collection, A. M. N. H. $\times \frac{3}{2}$.

The surface of the bone is largely missing, but the interior is represented by a natural cast of the glenoid region, which clearly shows the sutural relations of the three elements. The coracoid is perforated by the supracoracoid foramen. The metacoracoid has a wide contact with the scapula.

either in the marsupials or the monotremes, although in the two last named groups we had only one or two young specimens. In placental mammals it always forms the front part of the glenoid fossa immediately behind the coracoid; it is located at the anterior end of the glenoid ligament where the

latter is continuous with the long tendon of the biceps. This muscle in placentals passes through the capsule of the shoulder-girdle but in marsupials and monotremes, which apparently lack the subcoracoid, the biceps does not pass through the capsule but arises from the overlying coracoid (Carlsson, Leche). As the intrascapular position of part of the biceps is undoubtedly a neomorph in the placentals, we suspect that the appearance of a subcoracoid center of ossification is also a neomorph, like the ossific centers

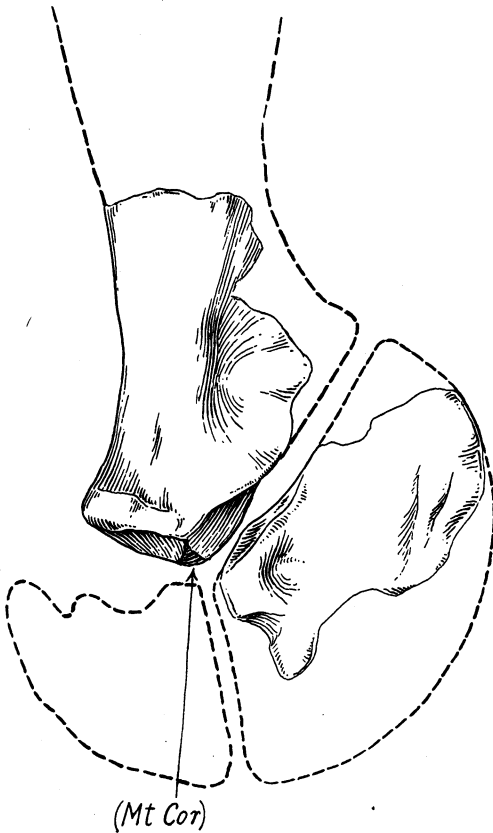

Fig. 15. Relations of the scapula, coracoid and metacoracoid in *Moschops capensis* Broom. Based on specimens in the Broom collection, A. M. N. H. The metacoracoid has a weak contact with the scapula.

in the acromian and the center at the lower tip of the coracoid. These and similar accessory centers appear to be associated with the attachments of muscles or ligaments.

Ameghino (1908), in a paper which the writer has only recently taken

into consideration, has given many carefully drawn figures of the coracoid region in various edentates. His identification of the coracoid elements in *Dicynodon* (*op. cit.*, p. 65), in the opinion of the writer, is correct, but he agrees with Howes in regarding the "subcoracoid" of mammals as the homologue of the reptilian metacoracoid, a conclusion which the writer has felt obliged to abandon. His identification of the main coracoid of Crocodilia, lizards, and ichthyosaurs as "metacoracoid" is not in accordance with the cogent evidence since secured by Professor Williston, which tends to show that the single coracoid of these reptiles represents the anterior, or perforated

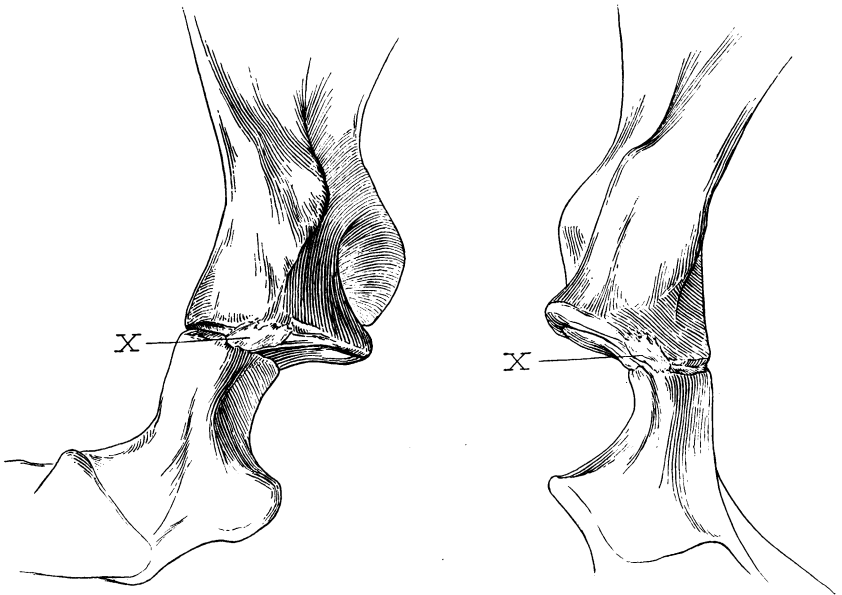


Fig. 16. Posterior aspect of the right and of the left glenoid region of an immature *Echidna aculeata*. Considerably enlarged.

A small epiphyseal (?) ossicle (X) is present on both sides at the posterior margin of the glenoid fossa and at the sutural junction of the scapula and coracoid. While in the right position for a vestigial metacoracoid, its true meaning and homology are very doubtful.

coracoid. In his figure (p. 76) of an abnormal pectoral girdle of *Echidna* the "precoracoid" is precisely in the position of the glenoid portion of the precoracoid of therapsid reptiles. If this be confirmed as a fact it would tend to some extent to support his conclusion.

In conclusion, the interpretation of the coracoid complex herein provisionally adopted may be summarized thus:

	PLACENTALS	MARSUPIALS	MONOTREMES	PRIM. PERMIAN REPTILES	MODERNIZED REPTILES	BIRDS
EPICORACOID	Absent in adults	Vestigial in embryos	Well developed	Probably present as a thin sheet of bone	Present	? "Precoracoid" of <i>Ratites</i>
CORACOID	Coracoid process	Coracoid process	Coracoid	"Precoracoid"	Coracoid	Coracoid
METACORACOID	Absent	Absent	Absent	Well developed	Absent	Absent
SUBCORACOID	Present (Neomorph)	Not developed	Not developed	Not developed	Not developed	Not developed

LITERATURE REFERRED TO IN PART VI

- AMEGHINO, F. 1908. El Arco Escapular de los Edentados y Monotremes y el Origen Reptiloide de estos dos Grupos de Mamíferos. *An. d. Mus. Nac. d. Buenos Aires*, (3^a, t. x) XVII, pp. 1-91.
- BROOM, R. 1899. On the development and morphology of the marsupial shoulder girdle. *Trans. Roy. Soc. Edinb.*, XXXIX, part 3, pp. 749-770.
1902. On the early condition of the shoulder girdle in the polyprotodont marsupials *Dasyurus* and *Perameles*. *Journ. Linn. Soc. (Zool.)*, XXVIII, pp. 449-454.
1903. On the structure of the shoulder girdle in *Lystrosaurus*. *Ann. So. Afr. Mus.*, IV, part 2, pp. 139-141, 2 text figs.
1906. Note on the lacertilian shoulder girdle. *Trans. So. Afr. Philos. Soc.*, XVI, part 4, Dec., pp. 373-375.
1912. The morphology of the coracoid. *Anat. Anz.*, XLI, pp. 625-631.
- CUVIER, GEORGE AND LAURILLARD, C. & L. No date. *Anatomie Comparée. Recueil de Planches de Myologie*.
- GREGORY, W. K. 1915. Present status of the problem of the origin of the Tetrapoda. *Ann. N. Y. Acad. Sci.*, XXVI, pp. 317-383. [Discussion of the coracoid problem, pp. 369-375, figs. 12-15.]
- HOWES, G. B. 1887. The morphology of the mammalian coracoid. *Journ. Anat. and Phys.*, pp. 190-198.
1893. On the coracoid of the terrestrial Vertebrata. *Proc. Zool. Soc. London*, pp. 585-592, 2 text figs.
- LYDEKKER, R. 1893. Note on the coracoidal element in adult sloths with remarks on its homology. *Proc. Zool. Soc. London*, pp. 172-174, 1 text fig.
- McKAY, W. J. S. 1894. The morphology of the muscles of the shoulder-girdle in monotremes. *Proc. Linn. Soc. N. S. Wales*, (2) IX, part 2 [volume issued 1895], pp. 263-360, Pls. xx-xxiii. [Extensive review of literature critically considered.]
- MIVART, ST. GEORGE. 1865-1866. On some points in the anatomy of *Echidna hystrix*. *Trans. Linn. Soc. London*, XXV, pp. 379-403, 2 Pls.
- OSAWA, GAKUTARO. 1898. Beiträge zur Anatomie der Hatteria punctata. *Archiv. für Mikros. Anat. u. Ent.*, LI, pp. 481-691, 53 text figs.
- PARKER, W. K. 1867. A monograph on the structure and development of the shoulder girdle and sternum. Ray Society.
- ROLLESTON, GEORGE. 1869. On the homologies of certain muscles connected with the shoulder-joint. *Trans. Linn. Soc. London*, XXVI, pp. 609-629.
- WATSON, D. M. S. 1917. The Evolution of the Tetrapod Shoulder Girdle and Forelimb. *Journal of Anatomy*, LII, part 1, pp. 1-63.
- WESTLING, CHARLOTTE. 1889. Anatomische Untersuchung über Echidna. *Bihang k. Svenska Vet.-Akad. Handlingar*, XV, Afd. 4, No. 3, pp. 1-71, 6 Pls.
- WILLISTON, S. W., CASE, E. C., AND MEHL, M. G. 1913. Permocarboneous vertebrates from New Mexico. Carnegie Institution of Washington Publication No. 181.
- [Professor Williston's views of the homologies of the coracoid and metacoracoid, p. 50.]
- WILSON, J. T. AND McKAY, W. J. STEWART. 1893. On the homologies of the borders and surfaces of the scapula in monotremes. *Proc. Linn. Soc. N. S. Wales*, (2) VIII, part 3, Oct. [volume issued 1894], pp. 377-388, Pl. xxi.

SUMMARY AND CONCLUSIONS

BY W. K. GREGORY

(1) The homologies of the limb muscles in reptiles and mammals as worked out by Fürbringer and Gadow from the innervation and from the origin, insertion, and relations of the muscles are, with few exceptions, adopted provisionally as the basis of the present work.

(2) The supposed homologies of the muscles of the pectoral region of reptiles and mammals are summarized on pages 477-479.

(3) The supposed homologies of the muscles of the pelvic region of reptiles, birds, and mammals are summarized on pages 504-505.

(4) The provisionally adopted homologies of the tail muscles of reptiles and mammals are summarized on pages 506-507.

(5) The general locations of the principal muscles of the pectoral and pelvic regions of *Cynognathus* are inferred after a critical comparison of the corresponding skeletal parts of *Cynognathus* and related forms with those of recent reptiles and mammals, in which the skeletal characters are correlated with known arrangements of the muscles. *Cynognathus* is a favorable subject for this kind of reconstruction because its girdles and limbs, while fundamentally reptilian, exhibit certain well marked modifications in the direction of the mammalian, and especially of the monotreme, type; so that it is fair to assume that the musculature of these parts was equally progressive toward the mammalian type. The inferred positions of the muscles of *Cynognathus* are given on pages 451-502 and in plates XXXIX-XLII, XLIV, XLV, while some of the reasons for these conclusions are discussed on pages 508-514.

(6) The chief contrasts in skeletal characters and musculature of the girdles and limbs between the primitive reptile *Sphenodon* and a highly specialized bipedal mammal (man) are correlated with equal differences in posture and it is pointed out that these wide contrasts are, to a certain extent, mediated by the conditions observable in the monotremes (pp. 509, 513).

(7) As bearing especially on the musculature of *Cynognathus*, it is noted (p. 510) that this animal shares with *Sphenodon* the primitive reptilian character of the upper end of the scapula, while it resembles monotremes in the sharp reflection of the anterior border to form the spina scapulæ, which ends below in the acromial process for the clavicle. It is, therefore, inferred (p. 511) that the everted surface of the scapula was occupied on the anterior side chiefly by enlarged omotrachelian and levator scapulæ muscles, as in

monotremes, and that the postspinous fossa was already occupied, as in monotremes, by the infraspinus muscle (which is supposed to be a derivative of the reptilian scapulo-humeralis posterior). The coracoid region is, on the whole, nearer to the monotreme type in general form, but very probably differed in the lack or feeble development of an epicoracoid fenestra, from which it is inferred that the supraspinatus muscle was still a part of the supracoracoideus and had not yet migrated dorsally or driven out the omotrachelian from the postspinous surface.

(8) It is shown (pp. 512, 513) how the wide contrasts in the pelvic region between *Sphenodon*, a primitive crawling reptile, and *Homo*, an advanced bipedal mammal, are correlated with corresponding differences in the arrangement and form of the muscles and with equal differences in the normal posture and function of the limbs. Among other differences it is noted that in *Homo* the gluteal area on the ilium is greatly expanded and the insertions of the primitive tail muscles greatly reduced or absent; that the iliacus area on the front inner side of the ilium is also widely expanded; that a certain group of muscles, including psoas major, iliacus, and pectineus, has very probably been derived from the pubi-ischio-femoralis internus of reptiles, as held by Gadow and others (pp. 486, 504).

(9) It is noted (p. 513) that, in the form and musculature of the pelvis, the monotremes again mediate the difference between *Sphenodon* and *Homo* and that, as regards the skeletal parts, *Cynognathus* in turn divides the difference between *Sphenodon* and the monotremes. In *Cynognathus* the forward expansion of the gluteal area of the ilium and the robust development of this group of muscles are correlated with the development of a large external trochanter on the femur. In the construction of the pubi-ischiadic plate *Cynognathus* is much closer to monotremes than to either *Sphenodon* or *Alligator* and it is accordingly inferred (Pl. XLV) that the arrangement of the obturator externus, adductors, gracilis, obturator internus, quadratus femoris, gemelli, biceps, semitendinosus, and semimembranosus was fundamentally as in monotremes, although doubtless more primitive in some respects.

(10) The probable homologies of the pelvic muscles in reptiles and birds, as worked out chiefly by Gadow, are summarized in the table on pages 504, 505, in which also comparisons with monotreme and placental mammals are given.

(11) After a comparative study of the pelvis of *Struthio*, *Alligator*, *Cynognathus* and *Ornithorhynchus*, drawings are given (Plate XLVI) showing the location of the muscle areas in these animals and the inferred location of the muscle areas in a saurischian dinosaur *Ornitholestes hermanni*. It is noted (p. 515) that, in spite of the general resemblance of the ilium of thero-

podous dinosaurs to that of birds, their pelvis is of reptilian type, with the pubis directed downward and forward, instead of downward and backward, and, hence, that it is reasonable to infer that the lower pelvic muscles were still in their primitive reptilian positions, rather than in the backwardly displaced positions seen in ornithischian dinosaurs and birds. (Some further consequences of these facts will be discussed in a later number of these studies.)

(12) In a review of the origin and evolution of certain locomotor adaptations in the pectoral and pelvic regions it is noted that in the earlier stages of evolution the movements of the paired limbs were closely correlated with, and at first subordinate to, the undulatory movements of the axial skeleton and musculature (p. 517), while in the highest stages the limb movements and musculature become widely differentiated from those of the axial skeleton. At the same time the originally metameric character of the limb muscles is progressively disguised.

(13) In primitive tetrapods the pelvis is located at the intersection of three main series of muscles (p. 518): first, those running from the pelvis and femur forward; second, those running from the pelvis and femur backward; third, those running transversely from the pelvis to the limb, both above and below the femur.

(14) The deep gluteal muscles are specialized anterior portions of the lateral tail muscles, while the superficial gluteus and agitator caudæ have probably been derived from the obliquus abdominis externus, as suggested by Gadow (p. 518).

(15) In the most primitive reptiles the deep gluteal muscles and the gluteal surface of the ilium are but little expanded. In large, heavy, and highly specialized reptiles, on the contrary, the gluteal muscles and gluteal surface of the ilium become greatly expanded (p. 519).

(16) While the muscles of one side are moving the free limb forward, the corresponding muscles of the opposite side, with the assistance of the back and tail muscles, are holding up the body on the limb that is on the ground and preventing the body from falling or sagging to one side. Thus we have adaptational reasons, on the one hand, for the expansion of the ilium and the extension of the sacrum in animals that hold the body well raised from the ground and, on the other hand, for the decrease in size and retrogression of the sacrum in fully aquatic types, which are buoyed up by the water (pp 519, 520).

(17) In forward locomotion, both on the ground and in swimming, the pelvis as a whole is turned alternately from side to side and rocked in a transverse plane. An attempt is made (p. 520) to describe the movements of the pelvis in connection with the action of the pelvic and caudal muscles,

(18) In primitive reptiles the ilium lies directly above the acetabulum, the pubis below and in front of it, and the ischium below and behind it. The femur in these types is ordinarily directed outward and the knees are permanently flexed. In mammals, on the other hand, the ilium is extended in front of the acetabulum, while the pubi-ischiadic rami lie chiefly behind it. The femur can be directed sharply forward and the knees can be widely extended. As a result of these changes, the obturators and adductors tend to pull the femur backward as well as inward, while the deep glutei also contribute a powerful anteroposterior component (pp. 521-523).

(19) A like purpose was probably served in birds and ornithischian dinosaurs by the anteroposterior extension of the ilium and of the anterior process of the pubis, as well as by the posterior extension of the pubis and ischium.

(20) In birds the "pectineal" or prepubic process serves for the attachment of one branch of the ambiens (rectus femoris). In ornithischian dinosaurs the greatly enlarged prepubic process may have served for the attachment not only of the ambiens and pubi-ischio-femoralis externus on the outer side, but also of the pubi-ischio-femoralis internus on the inner side (p. 521).

(21) In primitive reptiles the whole proximal end of the femur, forming a widely oval flattened head, was thrust into the wide, more or less three-sided acetabulum. In primitive mammals, on the other hand, the proximal end of the femur is differentiated into a spherical head, a distinct neck, and a projecting great trochanter for the attachment of the deep gluteal muscles. These and other differences were correlated with the contrasting posture of the limbs during locomotion in reptiles and mammals (pp. 524, 525).

(22) The fore limb of primitive vertebrates presents many analogies in structure and function with the hind limbs (p. 525). Just as in the hind limbs there is a set of muscles running from the vertical blade of the girdle posteriorly, a second set running from the girdle anteriorly and a third set running from the girdle transversely both above and below the fulcrum.

(23) The origin and subsequent disappearance of the cleithrum is referred to (p. 526), as well as the freeing of the pectoral girdle from its former attachment to the occiput.

(24) Primitive tetrapods still retain much of the piscine mode of undulation of the body in anteroposterior progression. This is accomplished partly through the axial musculature, partly through the action of the longitudinal muscles running along the side of the neck to the scapula and from the scapula back to the ribs. The lateral movements of the pectoral arch and sternum are described (pp. 526, 527), as well as the correlated movements of the fore and hind limbs in quadrupedal reptiles (p. 527).

(25) The various trochanters of the femur in reptiles, birds, and mammals are reviewed, and the relations of the trochanters to the muscles are considered (pp. 328-335). It is concluded that the lesser trochanter of mammals and the fourth trochanter of birds and dinosaurs are divergent derivatives of the internal trochanteric, or adductor, crest of primitive reptiles. The lesser trochanter of mammals, representing the upper or proximal part of the primitive trochanteric crest, points forward and is associated with the pubi-ischiofemoralis internus (= iliopsoas + pectineus). The fourth trochanter, derived from the more distal part of the primitive trochanteric crest, points backward and is associated especially with the adductors and caudifemoralis. The third trochanter is a neomorph in placental mammals.

(26) A reconstruction of the skeleton of *Cynognathus crateronotus* Seeley (pp. 538-545) is attempted after repeated studies of the available material, and in the light of the facts and principles above noted. A revised description of the more salient skeletal characters is given. It is concluded that the cynodonts foreshadowed the mammalian grade in many well-known characters of the brain-case and jaws, in the differentiation of the dorsal and lumbar regions, in the eversion of the anterior border of the scapula to form the spina scapulæ, in the forward extension of the ilium, and in the characters of the manus and pes. On the other hand, they were by definition reptiles, since the quadrate still functioned as such and the squamosodentary joint was not yet established. They also retained the reptilian heritage in many other characters, e. g., the presence of true ribs in the lumbar region, the presence of a metacoracoid, the lack of a well developed prespinous fossa in the scapula, the large size of the acetabulum, and the width and flatness of the head of the femur. They were doubtless normally sluggish animals, with small reptilian brains and imperfect heat-conserving and heat-producing adaptations, capable perhaps of stealthy approach and a sudden rush (straightening the hind limb somewhat in this movement), but not to be compared in speed or endurance with predatory cursorial mammals.

(27) In the "Second Note on the Evolution of the Coracoid Elements in Reptiles and Mammals" (pp. 545-552) it is maintained that three distinct parts of the coracoid region are involved in the problem of the homologies of the "coracoids" of reptiles and mammals: viz, the epicoracoid, the true coracoid (precoracoid), and the metacoracoid, as defined above (p. 545). The arrangement of the coracobrachialis and biceps muscles in reptiles and mammals are cited in support of this view and it is also claimed (p. 546) that the Permian reptiles probably had a membranous epicoracoid in front of their precoracoids (or true coracoids). It is suggested that the metacoracoid

was only one of the many elements of the endoskeleton of primitive reptiles which, as it were, lacked vitality and were gradually eliminated in all later phyla and that mammals in this respect followed the same line of evolution as did all other tetrapods which have but a single coracoid. It is held (p. 548) that the "subcoracoid center" has nothing to do with the ancient metacoracoid elements but is a neomorph in the placental mammals, associated with the intrascapular attachment of the tendon of the long head of the biceps. A summary of the various coracoid elements of reptiles, birds and mammals is given on p. 551.

EXPLANATION OF PLATES

PLATE XXXIX

Diagrams showing the probable position of the chief muscles of the pectoral region in *Cynognathus*.

A¹ — Superficial muscles after the removal of the skin and of the sphincter colli.

A² — Deeper muscles after the removal of the sphincter colli, trapezius and latissimus dorsi.

PLATE XL

Scapulocoraco-metacoracoid of *Cynognathus crateronotus* (cast of original specimen) with the probable muscle areas.

A¹ — Medial aspect. A² — Lateral aspect.

This region is on the whole much more like that of *Ornithorhynchus* than like those of either *Sphenodon* or *Alligator*. The omotrachelian (= levator scapulæ superficialis superior of *Sphenodon*) had a wide area on the cranio-medial surface of the reflected anterior border (= spina scapulæ). The post-spinous fossa was probably occupied by a large infraspinatus (= scapulohumeralis posterior?). This muscle, however, according to Fürbringer, is not the homologue of the similarly placed scapulohumeralis posterior of *Sphenodon*, but has been derived from the supracoideus (epicoracohumeralis), a part of which is supposed to have migrated dorsally and crowded out the scapulohumeralis posterior. In that case the latter may possibly be represented by the infraspinatus secundus of ungulates. The teres minor may have been inserted on a small rugosity above the glenoid fossa; it may represent part of a reduced dorsalis scapulæ, the spino-deltoid representing the other part.

PLATE XLI

Inferred general position and relations of the chief muscles of the shoulder region in *Cynognathus* (A) as compared with the known facts in *Ornithorhynchus* (B). Right side, lateral aspect.

PLATE XLII

Inferred general position and relations of the muscles of the pectoral girdle in *Cynognathus* (A) as compared with the known facts in *Ornithorhynchus* (B). Front view.

In *Cynognathus* the right clavicle is omitted in order to expose the muscles beneath and behind it. The width across the opposite acromia is conjectural. The suprascapulae as restored are probably much too small.

PLATE XLIII

Musculature of the pelvic limbs of recent reptiles. After Gadow.

A.—*Hydrosaurus* (*Varanus*) *marmoratus*. Medio-ventral aspect of the right hind limb with oblique medial view of the right half of the pelvis and associated muscles. After Gadow, 1882, Fig. 36.

S, II. sacro-iliac articulation (disconnected).

a, b, c, plexus cruralis (first, second, third presacral nerves).

Of these, c gives a branch to the ambiens and another to the iliofemoralis; b contributes largely to the obturator nerve, which traverses the obturator foramen in the pubis. The sacral nerve (NS) is the nerve that issues between the two sacral vertebrae; its plexus (Pl. ischiadicus s. sacralis) sends branches to the caudi-iliofemoralis, the caudifemoralis and the pubi-ischio-tibialis and the femorotibialis (Gadow, 1882, Taf. XVII, Fig. 16).

The plexus pudendus (α) sends branches to the cloacal and perineal region, and to the caudifemoralis.

<i>rect.</i>	rectus abdominis
<i>p. is. f. int.</i>	pubi-ischiofemoralis internus, arising on inner surface of pubis and ischium
<i>p. is. f. ext.</i>	pubi-ischiofemoralis externus, arising on outer surface of pubis and ischium and seen through the thyroid fenestra
<i>e. il. tb.</i>	extensor iliotibialis
<i>amb.</i>	ambiens
<i>fm. tb.</i>	femorotibialis
<i>pb. tb.</i>	pubitibialis
<i>pb. is. tb.</i>	pubi-ischiotibialis
<i>tb. ant.</i>	tibialis anticus
<i>cap. int.</i>	} gastrocnemius
<i>cap. ext. gastr.</i>	
<i>fl. t. int.</i>	flexor tibialis internus
<i>pb. is. fm. post.</i>	pubi-ischiofemoralis posterior
<i>is. cd.</i>	ischiocaudalis
<i>cd. fm.</i>	caudifemoralis

B.—*Hatteria* (*Sphenodon*) *punctata*. Right pelvic region, ventral view. After Gadow, 1882, Fig. 40. Portions of the rectus abdominis ventralis and of the pubi-ischiotibialis have been cut away to show the underlying muscles.

<i>rect.</i>	rectus abdominis (ventralis)
<i>rect. int.</i>	rectus internus abdominis
<i>Sy. p., Sy. is.</i>	symphysis pubis, symphysis ischii
<i>p. is. f. ext.</i>	pubi-ischiofemoralis externus
<i>os. c.</i>	os cloacæ
<i>is. cd.</i>	ischiocaudalis
<i>p. is. f. int.</i>	pubi-ischiofemoralis internus, part III (inserted on the anterior and partly on the inner surface of the femur)
<i>cd. fm.</i>	tendon of the caudifemoralis near its insertion distal to the external trochanter
<i>is. fm.</i>	ischiofemoralis
<i>fm. tb.</i>	femorotibialis

<i>pb. tb.</i>	pubitibialis
<i>amb.</i>	ambiens
<i>fl. tb. int.</i>	flexor tibialis internus
<i>pb. is. tb.</i>	pubi-ischiotibialis
<i>fl. t. ext.</i>	flexor tibialis externus
<i>il. f.</i>	iliofemoralis

C.—Alligator mississippiensis. Pelvic region, lateral aspect. After Gadow, 1882, Fig. 34.

<i>quadr. lb.</i>	quadratus lumborum, extending downward and backward towards its insertion on the femur
<i>obl. ext.</i>	obliquus externus abdominis
<i>amb.</i>	ambiens, piercing quadratus lumborum on its way toward insertion on the ilium
<i>e. il. tb. 1, e. il. t. 2</i>	first and second branch of the extensor iliotibialis

The nerves in this region come from the crural plexus.

<i>il. fm.</i>	iliofemoralis
<i>f. t.</i>	femorotibialis

The long nerve behind the femorotibialis is the nervus obturatorius.

<i>il. fb. 1, il. fb. 2</i>	iliofibularis, parts 1, 2
<i>f. t. ext.</i>	flexor tibialis externus
<i>f. t. int.</i>	flexor tibialis internus
<i>cd. il. fm.</i>	caudi-iliofemoralis
<i>cd. fm.</i>	caudifemoralis
<i>y</i>	tendinous branch of the caudifemoralis running to the caput fibulæ
<i>is. cd.</i>	ischiocaudalis
<i>N. cut.</i>	cutaneous branch from the sacral plexus

D.—Hatteria (Sphenodon) punctata. Right side, latero-dorsal aspect, after the removal of sections of the extensor iliotibialis, iliofibularis and iliocaudalis. After Fürbringer, 1882, Fig. 39.

<i>os.</i>	ilium
<i>il. fb.</i>	iliofibularis
<i>cd. il. f.</i>	caudi-iliofemoralis
	long tendon of caudi-iliofemoralis
<i>il. cd.</i>	iliocaudalis
<i>pr. tr.</i>	transverse processes, above which run the segmental dorsal muscle of the tail (M. caudæ dorsalis)
<i>cd. fm.</i>	caudifemoralis
<i>rect.</i>	rectus abdominis
<i>p. l. p.</i>	processus lateralis pubis
<i>e. il. t.</i>	extensor iliotibialis (connecting anteromedially with the thin tendon of the pubi-ischiofemoralis internus, part I)
<i>p. is. f. int. (III)</i>	pubi-ischiofemoralis, part III
<i>amb.</i>	ambiens
<i>il. fm.</i>	iliofemoralis
<i>fm. tb.</i>	femorotibialis
<i>is. t.</i>	ischiotibialis
<i>fl. tb.</i>	flexor tibialis (internal head)

E.—Alligator mississippiensis. Sagittal section of the pelvic region, medial aspect. After Gadow, 1882, Fig. 33.

<i>obliq.</i>	obliquus abdominis
<i>transv.</i>	transversus abdominis
<i>quadr. lumb.</i>	quadratus lumborum

The segmental nerves in this region form part of the plexus cruralis.

p. is. f. int. (I) pubi-ischiofemoralis internus, part I.

This part is pierced by the obturator nerve which is seen passing between the os pubis (*o. p.*) and the ischium (*Sy. i.*)

p. is. f. ext. pubi-ischiofemoralis externus

is. f. ischiofemoralis

p. is. f. int. (III) pubi-ischiofemoralis internus, part III, arising from the inner surface of the 24th, 25th and 26th vertebræ. Medial to this muscle is the plexus sacralis.

p. is. f. post. pubi-ischiofemoralis posticus

cd. il. fm. caudi-iliofemoralis

cd. fm. caudifemoralis, attached to the chevrons

is. cd. ischiocaudalis

PLATE XLIV

First trial diagram showing the inferred general location and relations of the principal muscles of the pelvic region in *Cynognathus*.

<i>sacro. spin.</i>	sacrospinalis
<i>quadr. lumb.</i>	quadratus lumborum. This muscle may have extended further ventrally and might have even been attached to the upper part of the femur as in the alligator
<i>obl. abd. ext.</i>	obliquus abdominis externus, inserted partly on the epipubic bones
<i>sart.</i>	sartorius, derived from anterior part of extensor iliobtibialis, part X
<i>glut. max.</i>	ectogluteus tensor fasciæ, derived from posterior part of extensor iliobtibialis
<i>pub. isch. fem. int.</i>	pubi-ischiofemoralis internus (= psoas major + iliacus + pectineus). Probably much larger than as shown here
<i>ambiens</i>	ambiens (rectus femoris). The rest of the quadriceps (femorotibialis) is not shown
<i>caud. il. fem.</i>	caudi-iliofemoralis (giving rise to deep glutei, pyriformis, etc.)
<i>caud. fem.</i>	caudifemoralis, inserted on postero-medial surface of femur
<i>caud. dors.</i>	M. caudæ dorsalis (extensors)
<i>ilio. caud.</i>	iliocaudalis (abductor caudæ dorsalis)
<i>isch. caud.</i>	ischiocaudalis (abductor caudæ ventralis, coccygeus)
<i>add. brev.</i>	adductor brevis (= part of pubi-ischio-femoralis)
<i>add. long.</i>	adductor longus (= part of pubi-ischio-femoralis)
<i>gracilis</i>	(?derived from pubi-ischiotibialis)
<i>semimemb.</i>	semimembranosus (?derived from ischiotibialis)
<i>biceps</i>	?derived from iliofibularis

PLATE XLV

General location of the muscle areas of the pelvis of *Sphenodon* (*A*¹, *A*²), *Ornithorhynchus* (*B*) and *Cynognathus* (*C*). (Compare Plate XLVI).

*A*¹—*Sphenodon*, right half of pelvis, medial aspect. Muscle areas according to Osawa (1898) and Gadow (1882).

*A*²—The same, lateral aspect. Muscle areas according to Osawa and Gadow.

<i>S₁S₂</i>	articular surfaces for sacral vertebræ
<i>longiss. dorsi</i>	area for longissimus dorsi (including iliocostalis)
<i>cocc. iliac.</i>	area for coccygeo-iliacus (= m. caudæ dorsalis) + iliocaudalis
<i>il. tib.</i>	area for iliobtibialis (= extensor iliobtibialis I Gadow)
<i>ilio. fem.</i>	area for iliofemoralis
<i>ilio. fib.</i>	" " iliofibularis
<i>pub. tib.+ambiens</i>	" " pubitibialis and ambiens
<i>obl. abd.</i>	" " obliquus abdominis (on processus lateralis pubis)
<i>pub. isch. fem. ext.</i>	" " pubi-ischiotrochantericus externus (= p. i. fem. ext. Gadow)
<i>pub. isch. troch. int.</i>	" " for pubi-ischiotrochantericus internus Osawa (= p. i. femoralis int. Gadow)

<i>rect. abd.</i>	area for rectus abdominis (on epipubic cartilage)
<i>isch. troch.</i>	" " ischiotrochantericus Osawa (= pubi-ischiofemoralis posterior Gadow)
<i>cocc. isch.</i>	area for coccygeo-ischiadicus (Osawa) (= ischiocaudalis Gadow)
<i>isch. tib. post.</i>	area for ischiotibialis posticus Osawa (= Flexor tibialis internus Gadow)
<i>sph. clo.</i>	area for sphincter cloacæ (Osawa) (= Aftermuskeln α , β , γ , etc. Gadow)

B.—Ornithorhynchus. General location of the chief muscle areas of the pelvis. Oblique view from the right side and partly from below. Data chiefly from Coues.

<i>glut. min., glut. med.</i>	areas for the deep gluteal muscles (derived from iliofemoralis)
<i>iliacus, pectineus,</i> <i>ps. min.</i>	} areas for the iliacus pectineus and psoas minor muscles which collectively represent the pubi-ischiofemoralis internus. The psoas minor is attached to the "pectineal process" along with the sartorius.
<i>add. brev.</i>	
<i>add. long. add. mag.</i>	area for adductor brevis (= ?longus) adductor longus, magnus
The adductor series probably represents the more peripheral parts of the pubi-ischiofemoralis externus of <i>Sphenodon</i> , while the obturator externus represents the more central part.	
<i>pyram.</i>	area for pyramidalis abdominis
<i>rect. fem.</i>	" " rectus femoris (probably derived from ambiens)
<i>quad. fem.</i>	" " quadratus femoris (probably derived from pubi-ischiofemoralis posterior, along with obturator internus and gemellus inferior)
<i>semilend.</i>	area for semitendinosus (probably derived from flexor tibialis externus)
<i>biceps</i>	" " biceps (probably derived from iliofibularis)
<i>semimemb.</i>	" " semimembranosus, derived from flexor tibialis internus (ischio-tibialis)

C.—Cynognathus. Inferred location of muscle areas. Abbreviations as in preceding figures.

PLATE XLVI

General location of the principal muscle areas of the pelvis.

A.—Alligator, data chiefly from Gadow.

B.—Cynognathus, tentative location of areas.

C.—Struthio, data chiefly from Gadow. (Compare text figure 10).

D.—Ornitholestes, tentative location of areas. (Compare text figure 10).

The homology of the true adductor series of *Cynognathus* and mammals with the so-called adductors of birds seems doubtful. The adductors of mammals are more peripheral in position lying external to the obturator externus and derived at least in part from the ischiofemoralis of reptiles. The "adductor magnus" of birds on the contrary arises dorsal to the obturator externus and is beneath the obturator internus.

PLATE XLVII

Moschops capensis Broom. Mounted pelvis and hind limbs (A. M. N. H.), $\times \frac{2}{5}$, with tentative general location and direction of the principal pelvic muscles.

A¹.—Right side, lateral aspect.

A².—Front view, showing left limb directed outward and backward, right limb outward and forward.

PLATE XLVIII

A series of femora of reptiles and mammals illustrating the morphology of the femoral trochanters. Scales various.

Upper row, proximal view.

Middle row, front (anterosuperior) view.

Lower row, back (posteroinferior) view.

<i>cap.</i>	caput femoris
<i>tr. min.</i>	trochanter minor (lesser trochanter), homologous with
<i>tr. in.</i>	trochanter internus, homologous with
<i>tr. 4</i>	trochanter quartus
<i>tr. mj.</i>	trochanter major (great trochanter)
<i>col.</i>	collum femoris
<i>tr. 3</i>	trochanter tertius
<i>foss. tr.</i>	fossa trochanterica

The most ancient and primitive type is in the center (*Dimetrodon gigas*). This has a deep trochanteric fossa and a high internal trochanteric, or adductor, crest, which probably served for the attachment of the ischiofemoralis (adductors), pubi-ischiofemoralis externus (obturator externus) and pubi-ischiofemoralis internus (iliopsoas + pectineus). At the left of the primitive type is the Therapsid-Mammal series, culminating in the marsupial (*Myrmecobius*) and primitive placental (*Pachyæna*) types, in which the internal trochanteric crest gives rise to the lesser trochanter (for the iliopsoas + pectineus). On the right of *Dimetrodon* is a morphological series leading toward the dinosaurs and showing the derivation of the fourth trochanter (for the insertion of the ischiofemoralis and caudifemoralis) from the internal trochanteric crest.

PLATE XLIX

Ventral view of the coracoid region of (A) *Sphenodon*, (B) *Ornithorhynchus*, (C) *Homo*, showing the location of the principal muscle areas.

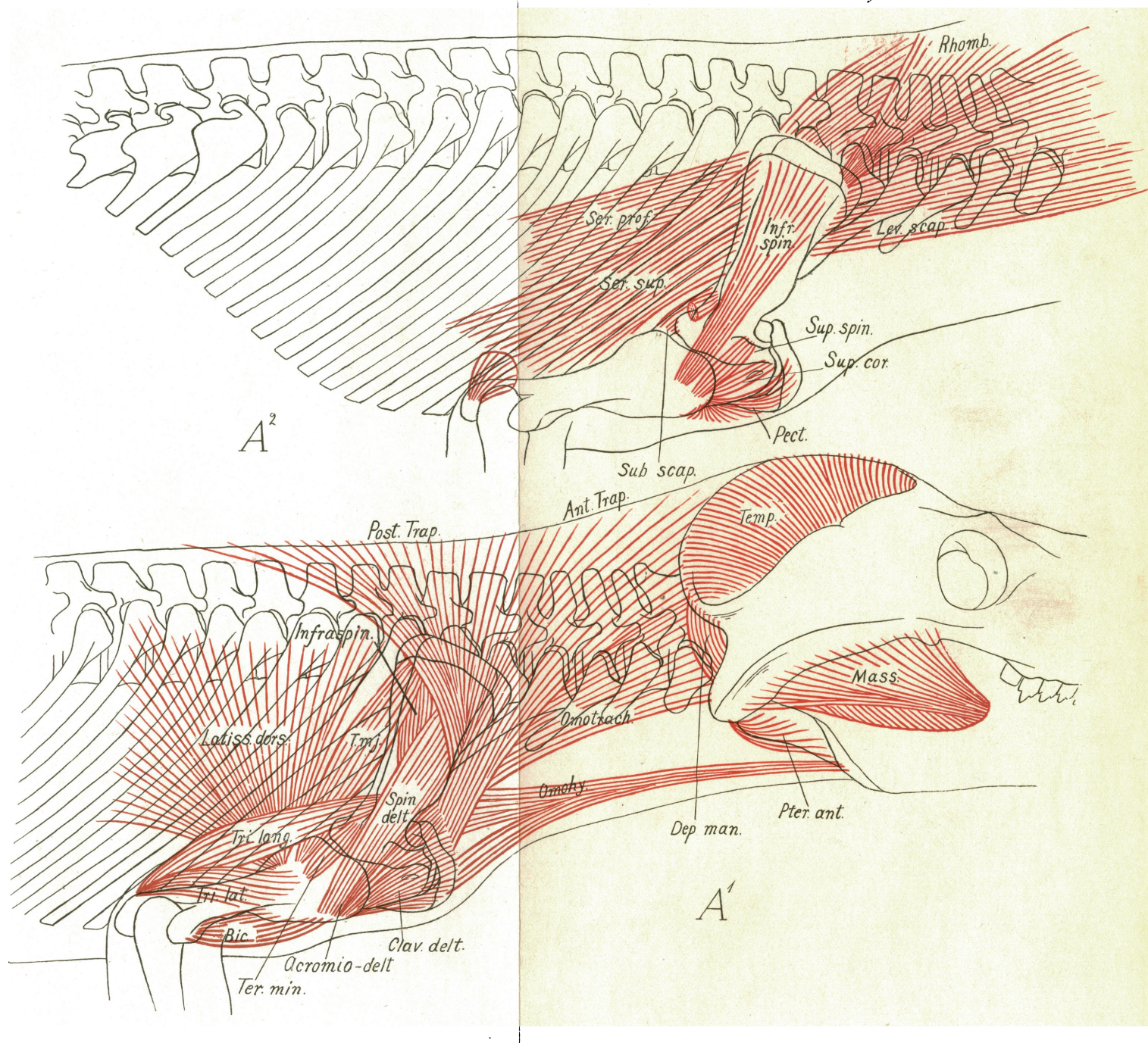
In all three cases the true coracoids serve for the origin of the coracobrachialis medius, the c. b. longus and the biceps muscles, while from the epicoracoids of *Sphenodon* and *Ornithorhynchus* arise the subcoraco-humeralis (= coracobrachialis brevis) and the supracoracoideus muscles. The "sub-coracoid" centre of mammals is probably a new structure associated with the intracapsular origin of the long head of the biceps.

The supraspinatus muscle of mammals may have been derived either from the scapulohumeralis anterior or from the supracoracoideus of primitive reptiles.

PLATE L

Inner surface of the left half of the pectoral girdle of *Iguana*, *Sphenodon*, *Alligator*, *Echidna*, *Moschops* and *Ornithorhynchus*.

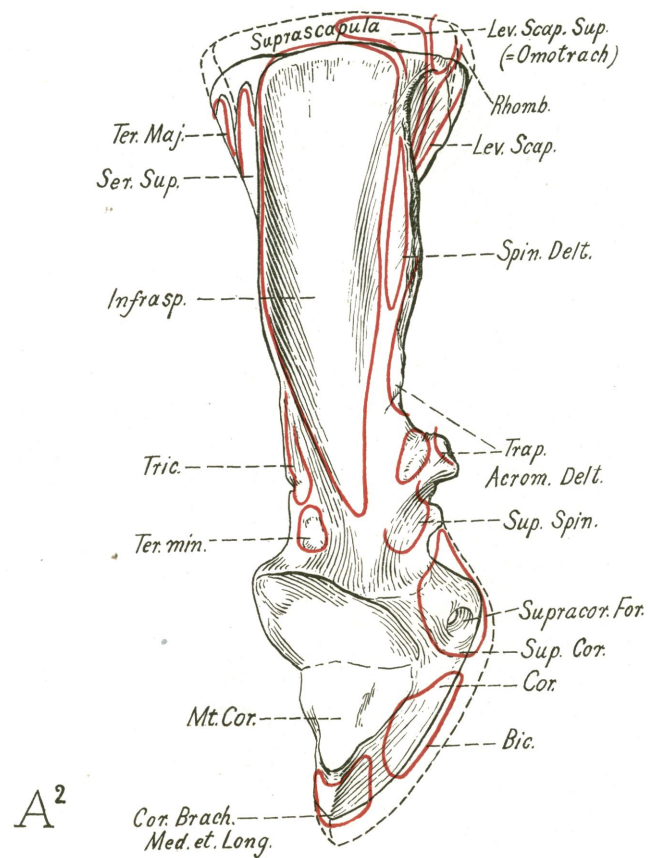
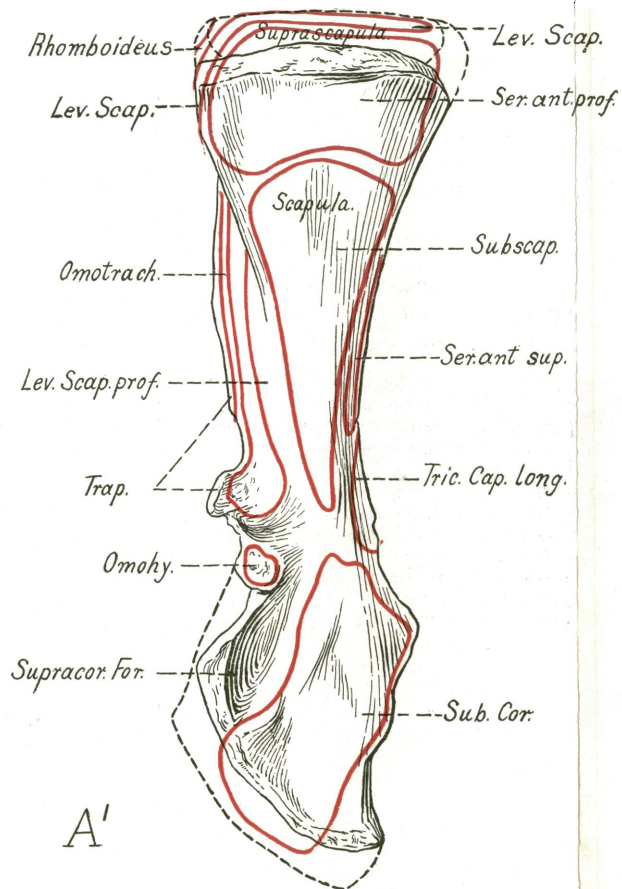
The most primitive conditions in the series are seen in the Permian reptile *Moschops*, which retains all the original elements including the cleithrum and the metacoracoid. The presence of a membranous epicoracoid is indicated by the form and relations of the coracoid in the mounted specimen. *Sphenodon* has lost the cleithrum and the metacoracoid but is otherwise primitive. In *Iguana* secondary vacuities are developed in the coracoid and scapula. In *Alligator* the single coracoid, still pierced by the supracoracoid foramen, is extended transversely; the clavicle is lacking but the epicoracoid is probably represented by the membrana episterno-coracoideus. In *Echidna* and *Ornithorhynchus* the metacoracoid is lost and the epicoracoid, perhaps in adaptation to fossorial habits, becomes thick and well ossified. The coracoid is not perforated by the supracoracoid nerve, which passes through the large secondary opening above the epicoracoid. A vestigial ossicle (X) in a certain immature specimen of *Echidna* has somewhat the position of the metacoracoid but is of very doubtful homology.



Diagrams showing the probable position of the chief muscles of the pectoral region in *Cynognathus*.

A¹—Superficial muscles after the removal of the skin and of the sphincter colli.

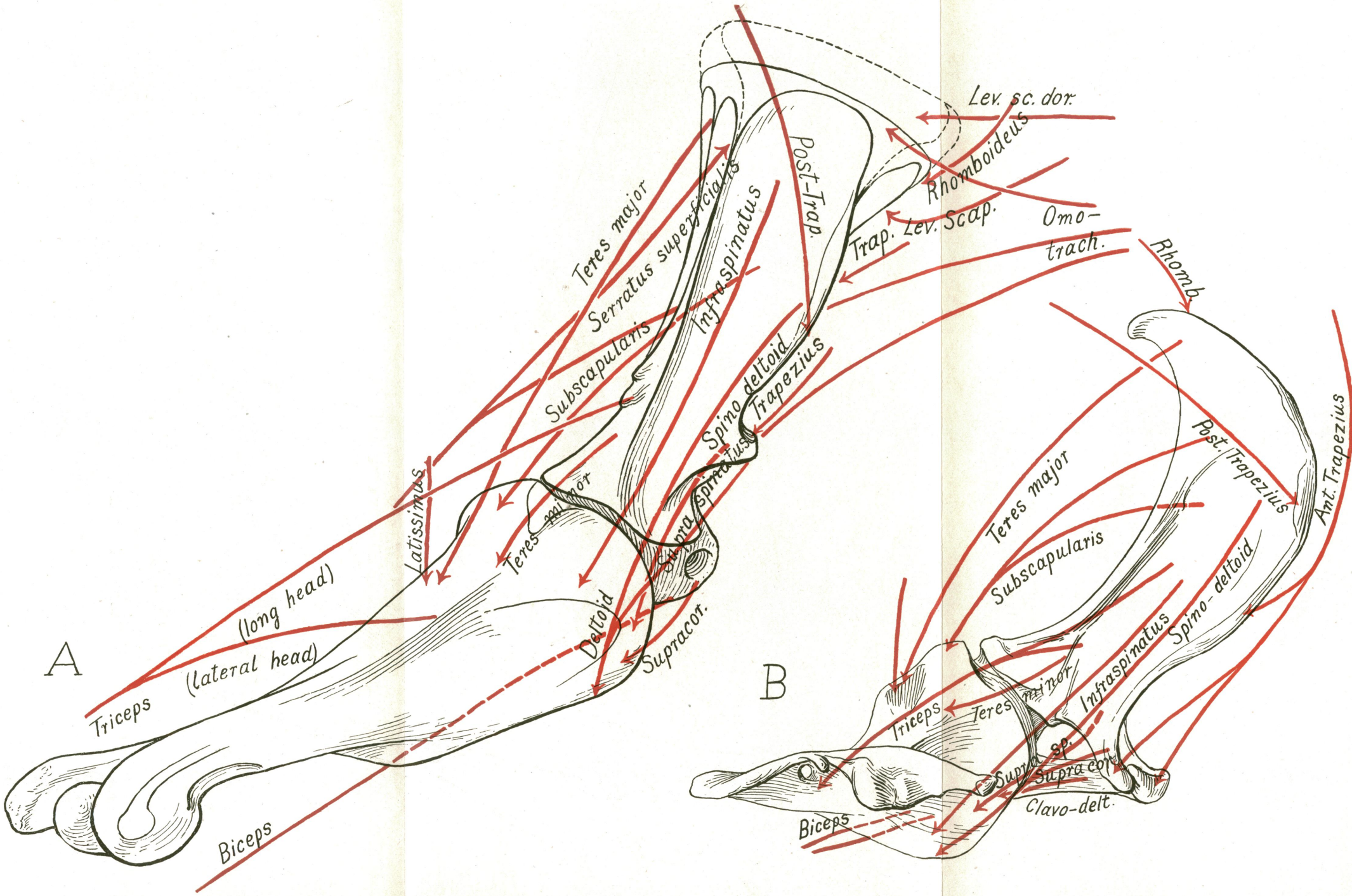
A²—Deeper muscles after the removal of the sphincter colli, trapezius and latissimus dorsi.



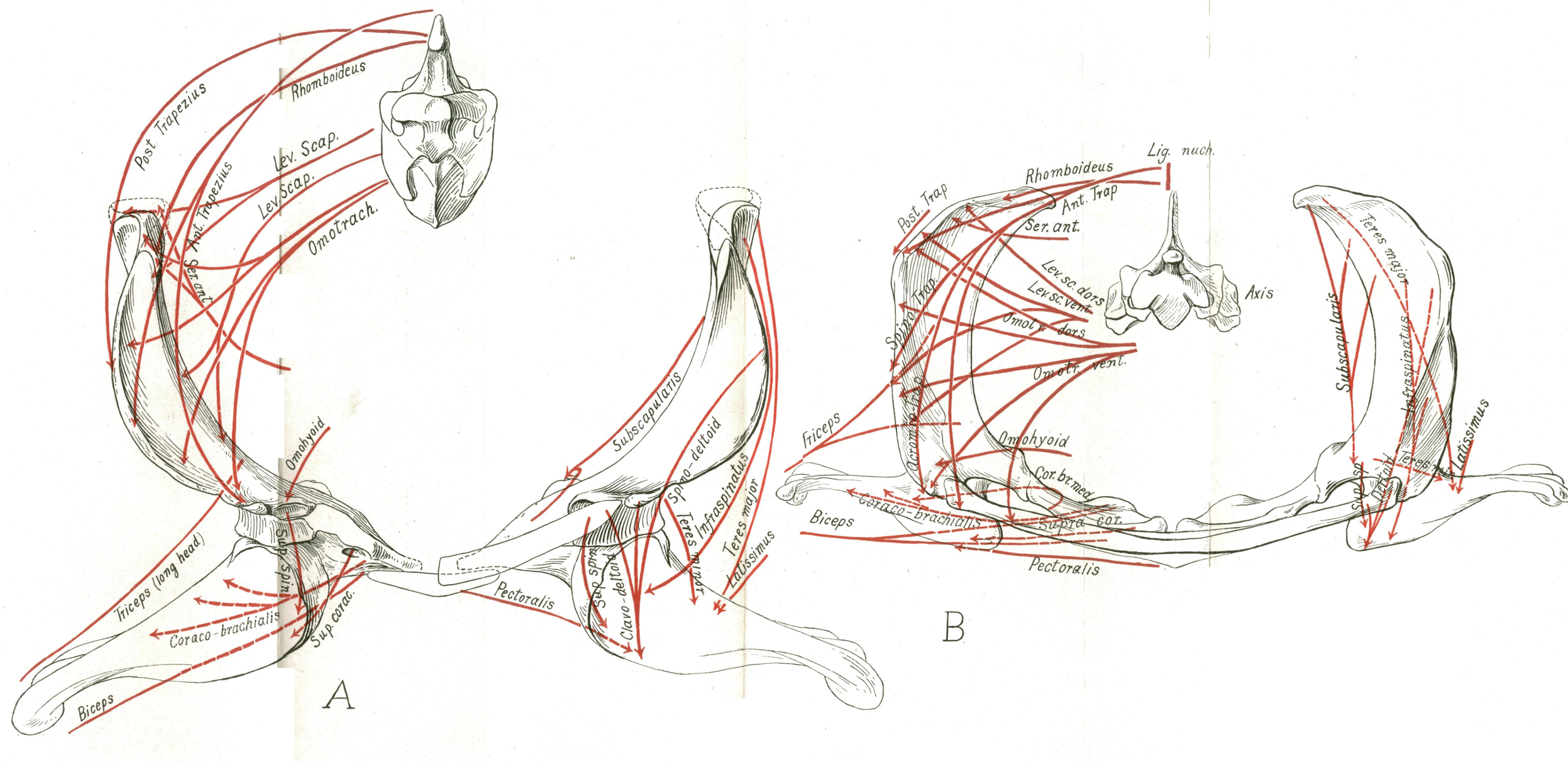
Scapulocoraco-metacoracoid of *Cynognathus crateronotus* (cast of original specimen) with the probable muscle areas.

A¹—Medial aspect. A²—Lateral aspect.

This region is on the whole much more like that of *Ornithorhynchus* than like those of either *Sphenodon* or *Alligator*. The omotrachelian (= levator scapulæ superficialis superior of *Sphenodon*) had a wide area on the cranio-medial surface of the reflected anterior border (= spina scapulæ). The post-spinous fossa was probably occupied by a large infraspinatus (= scapulohumeralis posterior?). This muscle, however, according to Fürbringer, is not the homologue of the similarly placed scapulohumeralis posterior of *Sphenodon*, but has been derived from the supracoideus (epicoracohumeralis), a part of which is supposed to have migrated dorsally and crowded out the scapulohumeralis posterior. In that case the latter may possibly be represented by the infraspinatus secundus of ungulates. The teres minor may have been inserted on a small rugosity above the glenoid fossa; it may represent part of a reduced dorsalis scapulæ, the spino-deltoid representing the other part.

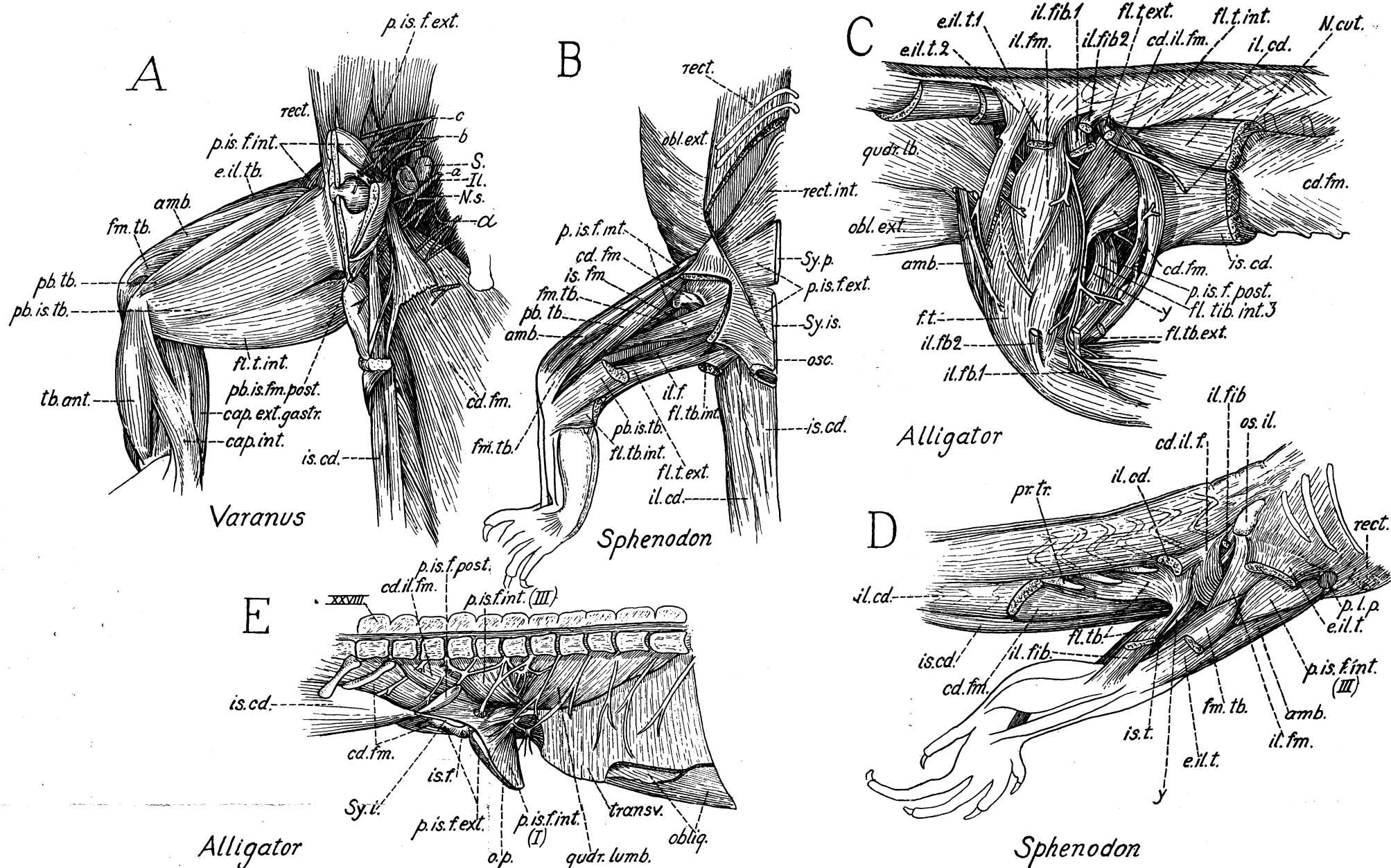


Inferred general position and relations of the chief muscles of the shoulder region in *Cynognathus* (*A*) as compared with the known facts in *Ornithorhynchus* (*B*). Right side, lateral aspect.



Inferred general position and relations of the muscles of the pectoral girdle in *Cynognathus* (A) as compared with the known facts in *Ornithorhynchus* (B). Front view.

In *Cynognathus* the right clavicle is omitted in order to expose the muscles beneath and behind it. The width across the opposite acromia is conjectural. The suprascapulæ as restored are probably much too small.



Musculature of the pelvic limbs of recent reptiles. After Gadow.
A.—Hydrosaurus (Varanus) marmoratus. Medio-ventral aspect of the right hind limb with oblique medial view of the right half of the pelvis and associated muscles. After Gadow, 1882, Fig. 36.

S, II. sacro-iliac articulation (disconnected).
 a, b, c, plexus cruralis (first, second, third presacral nerves).

Of these, c gives a branch to the ambiens and another to the iliofemoralis; b contributes largely to the obturator nerve, which traverses the obturator foramen in the pubis. The sacral nerve (NS) is the nerve that issues between the two sacral vertebrae; its plexus (Pl. ischidicus s. sacralis) sends branches to the caudi-iliofemoralis, the caudifemoralis and the pubi-ischio-tibialis and the femorotibialis (Gadow, 1882, Taf. XVII, Fig. 16).

The plexus pudendus (a) sends branches to the cloacal and perineal region, and to the caudifemoralis.

rect.	rectus abdominis
p. is. f. int.	pubi-ischiofemoralis internus, arising on inner surface of pubis and ischium
p. is. f. ext.	pubi-ischiofemoralis externus, arising on outer surface of pubis and ischium and seen through the thyroid fenestra
e. il. tb.	extensor iliobtibialis
amb.	ambiens
fm. tb.	femorotibialis
pb. tb.	pubitibialis
pb. is. tb.	pubi-ischiotibialis
tb. ant.	tibialis anticus
cap. int.	gastrocnemius
cap. ext. gastr.	flexor tibialis internus
fl. t. int.	pubi-ischiofemoralis posterior
pb. is. fm. post.	ischio-caudalis
is. cd.	ischio-caudalis
cd. fm.	caudifemoralis

B.—Hatteria (Sphenodon) punctata. Right pelvic region, ventral view. After Gadow, 1882, Fig. 40. Portions of the rectus abdominis ventralis and of the pubi-ischiotibialis have been cut away to show the underlying muscles.

rect.	rectus abdominis (ventralis)
rect. int.	rectus internus abdominis
Sy. p., Sy. is.	symphysis pubis, symphysis ischii
p. is. f. ext.	pubi-ischiofemoralis externus
os. c.	os cloacae
ic. cd.	ischio-caudalis
p. is. f. int.	pubi-ischiofemoralis internus, part III (inserted on the anterior and partly on the inner surface of the femur)
cd. fm.	tendon of the caudifemoralis near its insertion distal to the external trochanter
is. fm.	ischiofemoralis
fm. tb.	femorotibialis
pb. tb.	pubitibialis
amb.	ambiens
fl. tb. int.	flexor tibialis internus
pb. is. tb.	pubi-ischiotibialis
fl. t. ext.	flexor tibialis externus
il. f.	iliofemoralis

C.—Alligator mississippiensis. Pelvic region, lateral aspect. After Gadow, 1882, Fig. 34.

quadr. lb.	quadratus lumborum, extending downward and backward towards its insertion on the femur
obl. ext.	obliquus externus abdominis

amb.	ambiens, piercing quadratus lumborum on its way toward insertion on the ilium
e. il. tb. 1, e. il. tb. 2	first and second branch of the extensor iliobtibialis

The nerves in this region come from the crural plexus.

il. fm.	iliofemoralis
f. t.	femorotibialis

The long nerve behind the femorotibialis is the nervus obturatorius.

il. fb. 1, il. fb. 2	iliofibularis, parts 1, 2
f. t. ext.	flexor tibialis externus
f. t. int.	flexor tibialis internus
cd. il. fm.	caudi-iliofemoralis
cd. fm.	caudifemoralis
v.	tendinous branch of the caudifemoralis running to the caput fibulae
is. cd.	ischio-caudalis
N. cut.	cutaneous branch from the sacral plexus

D.—Hatteria (Sphenodon) punctata. Right side, latero-dorsal aspect, after the removal of sections of the extensor iliobtibialis, iliofibularis and ilio-caudalis. After Fürbringer, 1882, Fig. 39.

os. il.	ilium
il. fb.	iliofibularis
cd. il. f.	caudi-iliofemoralis
	long tendon of caudi-iliofemoralis
il. cd.	ilio-caudalis
pr. tr.	transverse processes, above which run the segmental dorsal muscle of the tail (M. caudæ dorsalis)
cd. fm.	caudifemoralis
rect.	rectus abdominis
p. l. p.	processus lateralis pubis
e. il. t.	extensor iliobtibialis (connecting anteromedially with the thin tendon of the pubi-ischiofemoralis internus, part I)
p. is. f. int. (III)	pubi-ischiofemoralis, part III
amb.	ambiens
il. fm.	iliofemoralis
fm. tb.	femorotibialis
is. t.	ischiotibialis
fl. tb.	flexor tibialis (internal head)

E.—Alligator mississippiensis. Sagittal section of the pelvic region, medial aspect. After Gadow, 1882, Fig. 33.

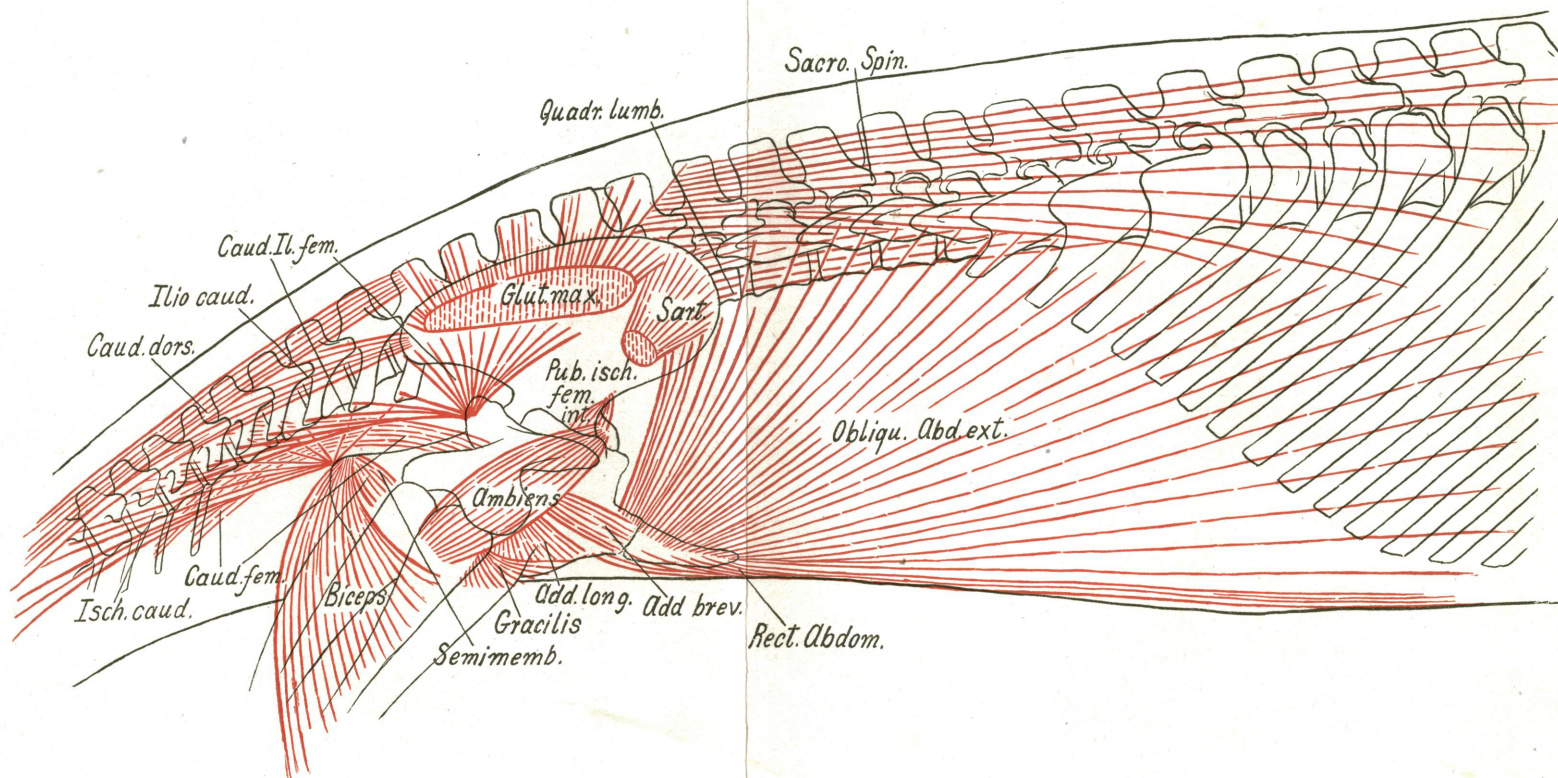
obl.	obliquus abdominis
transv.	transversus abdominis
quadr. lumb.	quadratus lumborum

The segmental nerves in this region form part of the plexus cruralis.

p. is. f. int. (I)	pubi-ischiofemoralis internus, part I.
--------------------	--

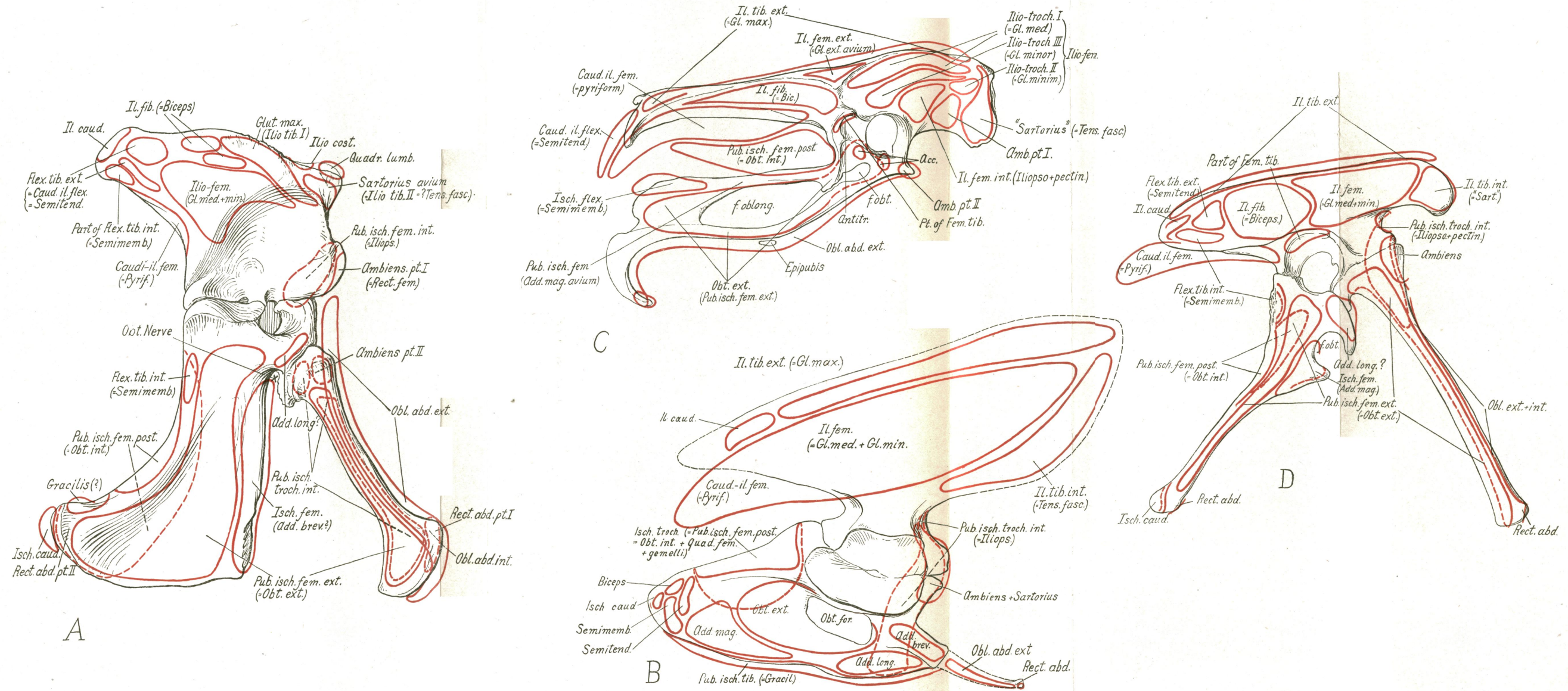
This part is pierced by the obturator nerve which is seen passing between the os pubis (o. p.) and the ischium (Sy. i.)

p. is. f. ext.	pubi-ischiofemoralis externus
is. f.	ischiofemoralis
p. is. f. int. (III)	pubi-ischiofemoralis internus, part III, arising from the inner surface of the 24th, 25th and 26th vertebrae. Medial to this muscle is the plexus sacralis.
p. is. f. post.	pubi-ischiofemoralis posticus
cd. il. fm.	caudi-iliofemoralis
cd. fm.	caudifemoralis, attached to the chevrons
is. cd.	ischio-caudalis



First trial diagram showing the inferred general location and relations of the principal muscles of the pelvic region in *Cynognathus*.

<i>sacro. spin.</i>	sacrospinalis
<i>quadr. lumb.</i>	quadratus lumborum. This muscle may have extended further ventrally and might have even been attached to the upper part of the femur as in the alligator
<i>obl. abd. ext.</i>	obliquus abdominis externus, inserted on the epipubic bones
<i>sart.</i>	sartorius, derived from anterior part of extensor iliotibialis, part X
<i>glut. max.</i>	ectogluteus+tensor fasciæ derived from posterior part of extensor iliotibialis
<i>pub. isch. fem. int.</i>	pubi-ischiofemoralis internus (= psoas major + iliacus + pectineus).
	Probably much larger than as shown here
<i>ambiens</i>	ambiens (rectus femoris). The rest of the quadriceps (femorotibialis) is not shown
<i>caud. il. fem.</i>	caudi-iliofemoralis (giving rise to deep glutei, pyriformis, etc.)
<i>caud. fem.</i>	caudifemoralis, inserted on postero-medial surface of femur
<i>caud. dors.</i>	M. caudæ dorsalis (extensors)
<i>ilio. caud.</i>	iliocaudalis (abductor caudæ dorsalis)
<i>isch. caud.</i>	ischio-caudalis (abductor caudæ ventralis, coccygeus)
<i>add. brev.</i>	adductor brevis (= part of pubi-ischio-femoralis)
<i>add. long.</i>	adductor longus (= part of pubi-ischio-femoralis)
<i>gracilis</i>	(?derived from pubi-ischiotibialis)
<i>semimemb.</i>	semimembranosus (?derived from ischiotibialis)
<i>biceps</i>	?derived from iliofibularis



General location of the principal muscle areas of the pelvis.

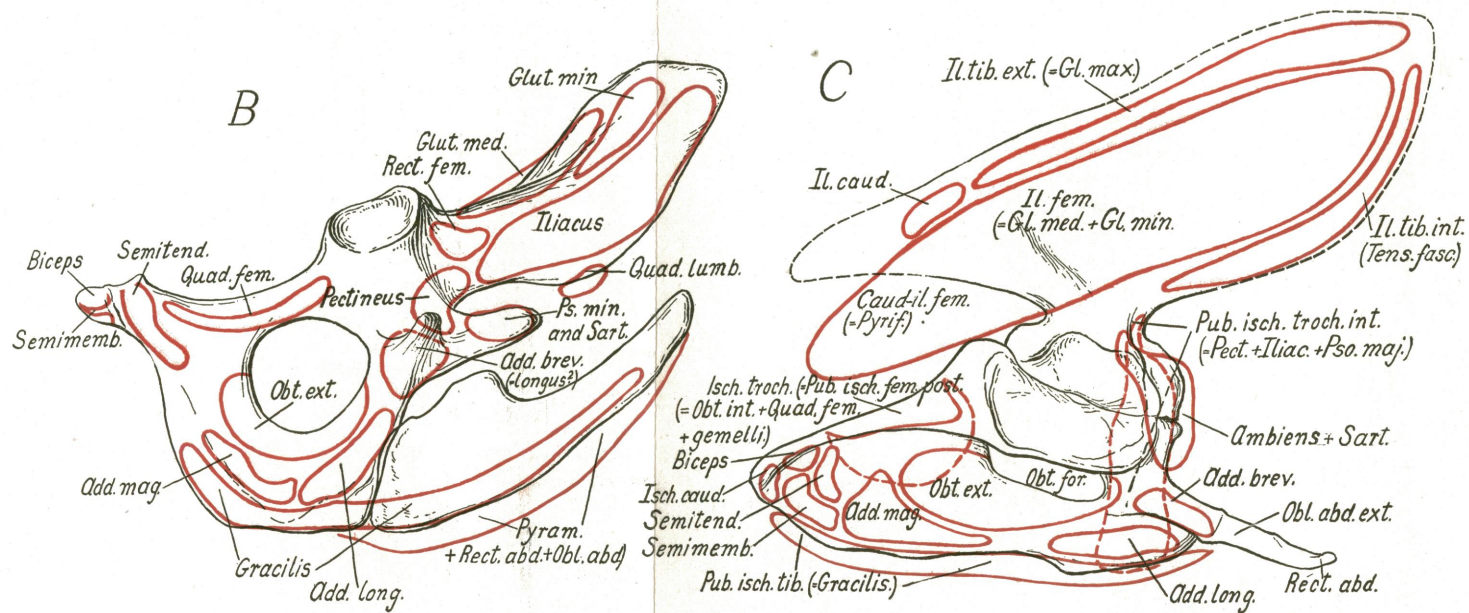
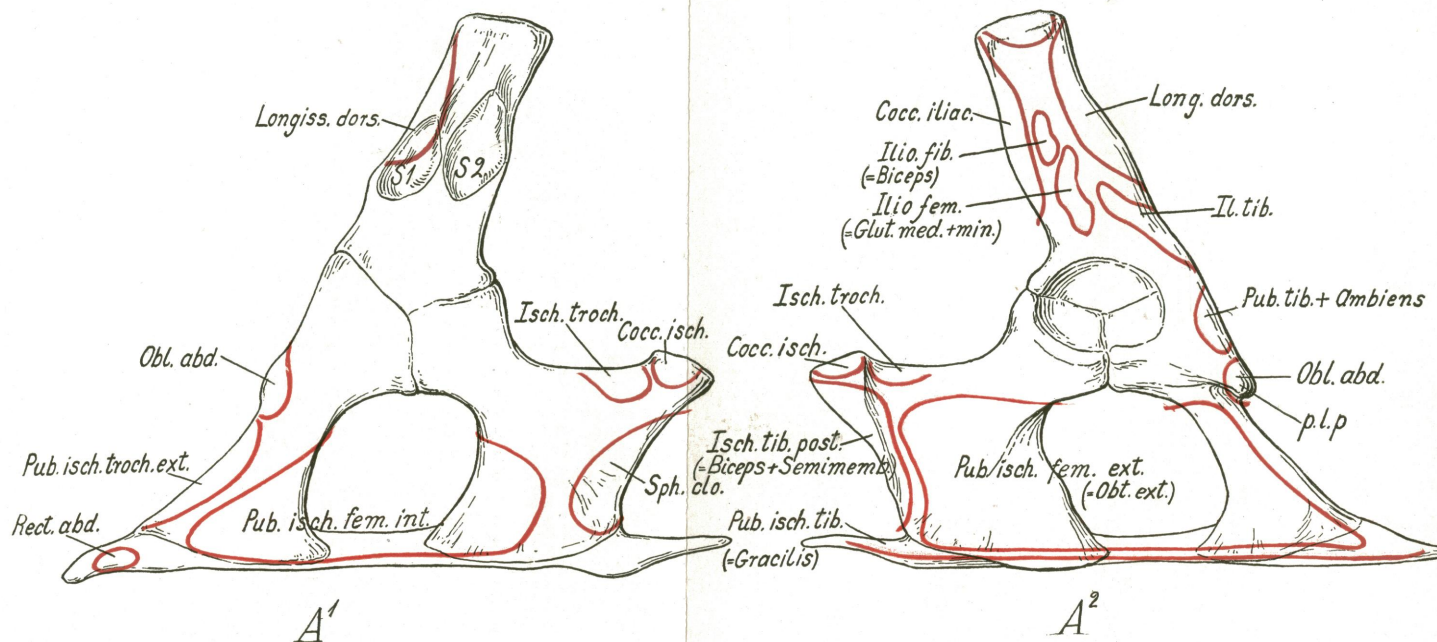
A.—*Alligator*, data chiefly from Gadow.

B.—*Cynognathus*, tentative location of areas.

C.—*Struthio*, data chiefly from Gadow. (Compare text figure 10).

D.—*Ornitholestes*, tentative location of areas. (Compare text figure 10).

The homology of the true adductor series of *Cynognathus* and mammals with the so-called adductors of birds seems doubtful. The adductors of mammals are more peripheral in position lying external to the obturator externus and derived at least in part from the ischiofemoralis of reptiles. The "adductor magnus" of birds on the contrary arises dorsad to the obturator externus and is beneath the obturator internus.



General location of the muscle areas of the pelvis of *Sphenodon*^(A¹, A²), *Ornithorhynchus* (B) and *Cynognathus* (C). (Compare Plate XLVI.)

A¹—*Sphenodon*, right half of pelvis, medial aspect. Muscle areas according to Osawa (1898) and Gadow (1882).

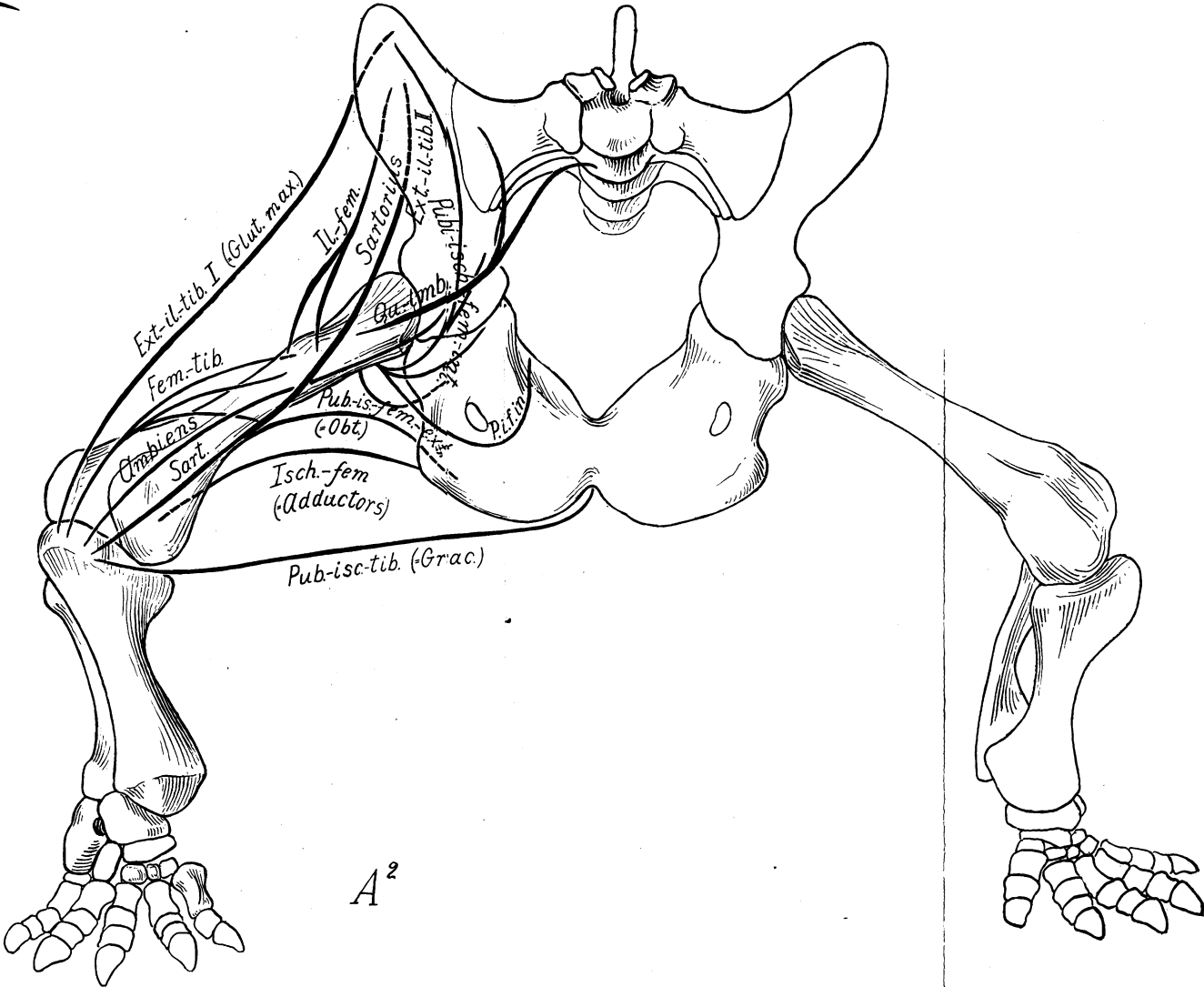
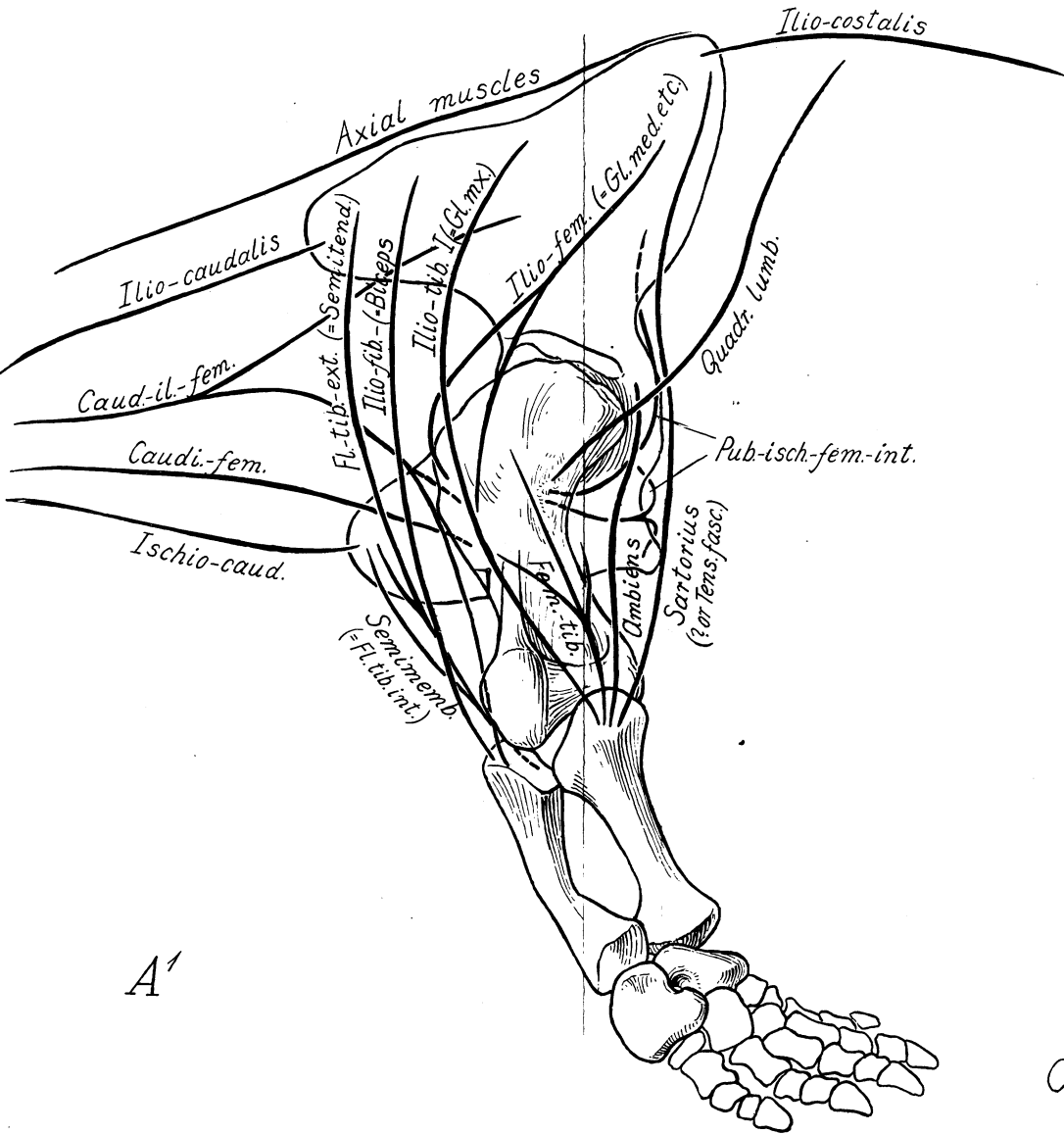
A²—The same, lateral aspect. Muscle areas according to Osawa and Gadow.

S ¹ S ²	articular surfaces for sacral vertebrae
longiss. dorsi	area for longissimus dorsi (including iliocostalis)
cocc. iliac.	area for coccygeo-iliacus (= m. caudæ dorsalis) + iliocaudalis
il. tib.	area for iliotibialis (= extensor iliotibialis I Gadow)
ilio. fem.	area for iliofemoralis
ilio. fib.	" " iliofibularis
pub. tib. + ambiens	" " pubitibialis and ambiens
obl. abd.	" " obliquus abdominis (on processus lateralis pubis)
pub. isch. fem. ext.	" " pubi-ischiotrochantericus externus (= p. i. fem. ext. Gadow)
pub. isch. troch. int.	" " for pubi-ischiotrochantericus internus Osawa (= p. i. femoralis int. Gadow)
rect. abd.	area for rectus abdominis (on epipubic cartilage)
isch. troch.	" " ischiotrochantericus Osawa (= pubi-ischiofemoralis posterior Gadow)
cocc. isch.	area for coccygeo-ischiadicus (Osawa) (= ischiocaudalis Gadow)
isch. tib. post.	area for ischiotibialis posticus Osawa (= flexor tibialis internus Gadow)
sph. clo.	area for sphincter cloacæ (Osawa) (= Aftermuskeln α, β, γ, etc. Gadow)

B.—*Ornithorhynchus*. General location of the chief muscle areas of the pelvis. Oblique view from the right side and partly from below. Data chiefly from Coues.

glut. min., glut. med.	areas for the deep gluteal muscles (derived from iliofemoralis)
iliacus, pectineus,	} areas for the iliacus pectineus and psoas minor muscles which collectively represent the pubi-ischiofemoralis internus. The psoas minoris is attached to the "pectineal process" along with the sartorius.
ps. min.	
add. brev.	area for adductor brevis (= ?longus)
add. long. add. mag.	adductor longus, magnus
The adductor series probably represents the more peripheral parts of the pubi-ischiofemoralis externus of <i>Sphenodon</i> , while the obturator externus represents the more central part.	
pyram.	area for pyramidalis abdominis
rect. fem.	" " rectus femoris (probably derived from ambiens)
quadr. fem.	" " quadratus femoris (probably derived from pubi-ischiofemoralis posterior, along with obturator internus and gemellus inferior)
semitend.	area for semitendinosus (probably derived from flexor tibialis externus)
biceps	" " biceps (probably derived from iliofibularis)
semimemb.	" " semimembranosus, derived from flexor tibialis internus (ischio-tibialis)

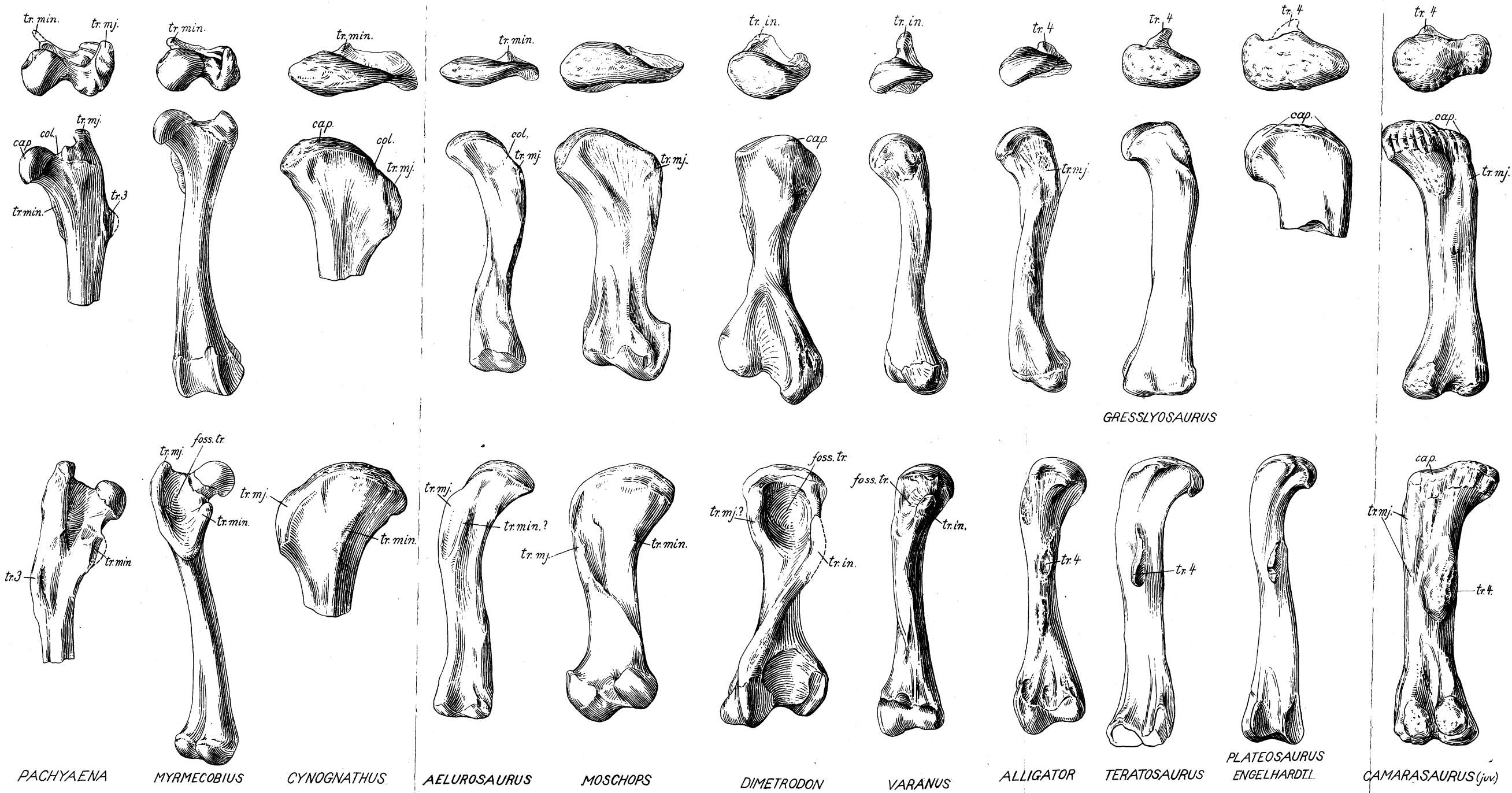
C.—*Cynognathus*. Inferred location of muscle areas. Abbreviations as in preceding figures.



Moschops capensis Broom. Mounted pelvis and hind limbs (A. M. N. H.), $\times \frac{1}{2}$, with tentative general location and direction of the principal pelvic muscles.

*A*¹.—Right side, lateral aspect.

*A*².—Front view, showing left limb directed outward and backward, right limb outward and forward.



A series of femora of reptiles and mammals illustrating the morphology of the femoral trochanters. Scales various.

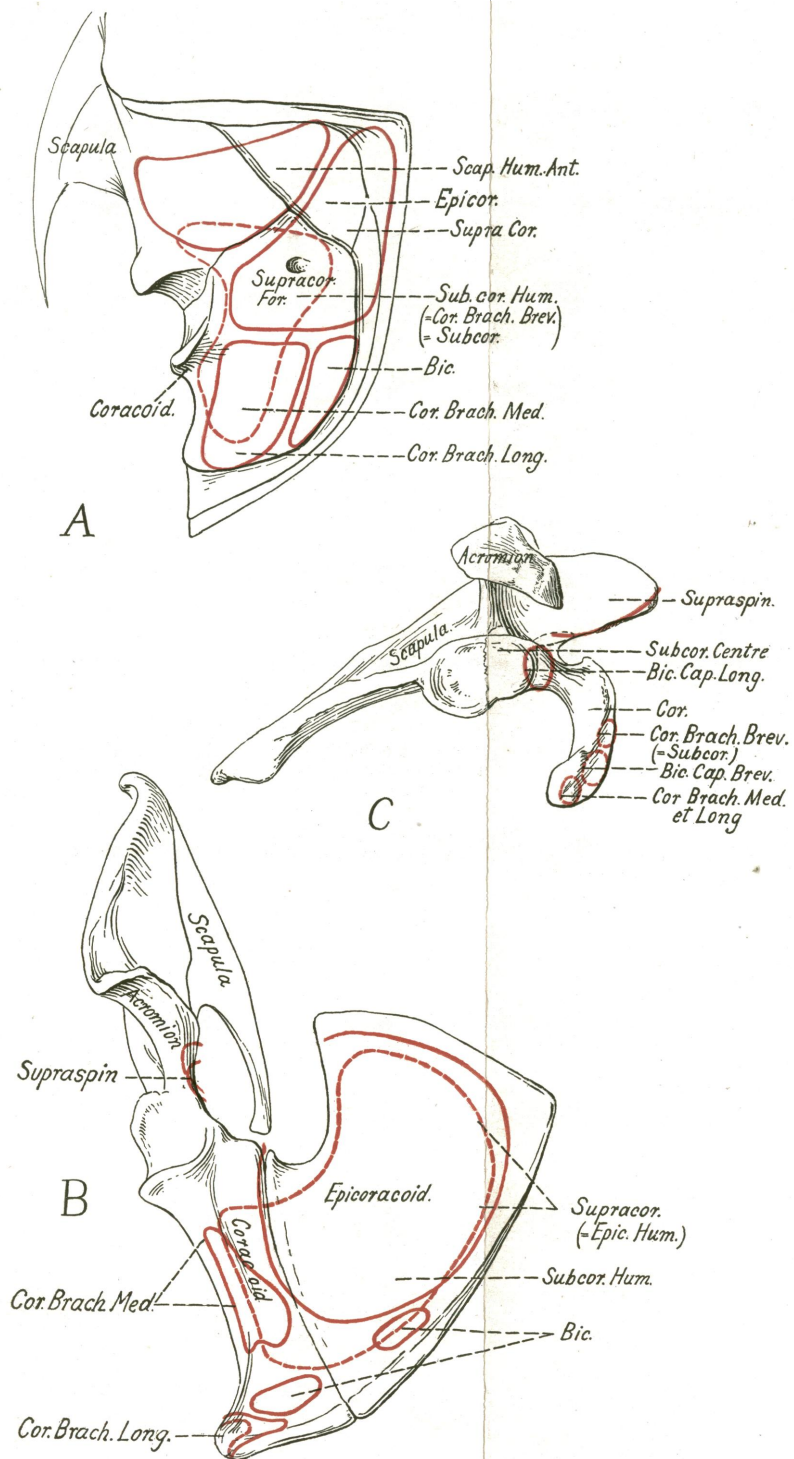
Upper row, proximal view.

Middle row, front (anterosuperior) view.

Lower row, back (posteroinferior) view.

<i>cap.</i>	caput femoris
<i>tr. min.</i>	trochanter minor (lesser trochanter), homologous with
<i>tr. in.</i>	trochanter internus, homologous with
<i>tr. 4</i>	trochanter quartus
<i>tr. mj.</i>	trochanter major (great trochanter)
<i>col.</i>	collum femoris
<i>tr. 3</i>	trochanter tertius
<i>foss. tr.</i>	fossa trochanterica

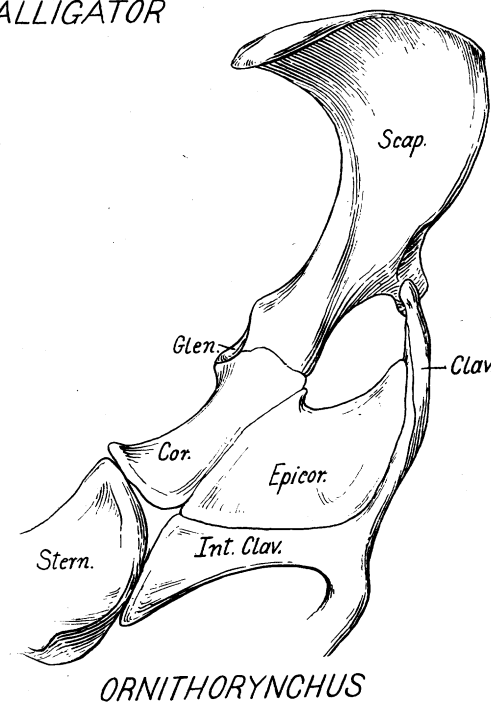
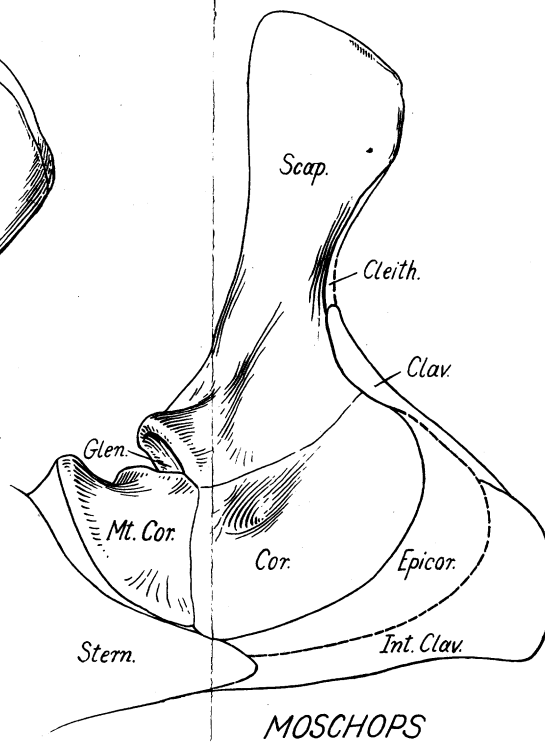
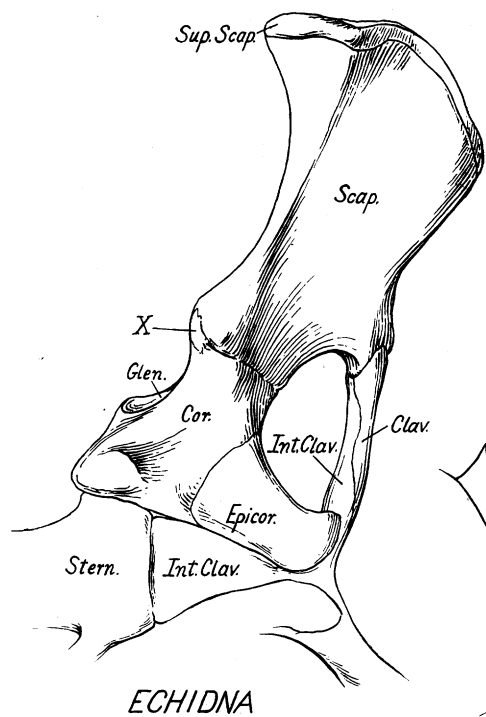
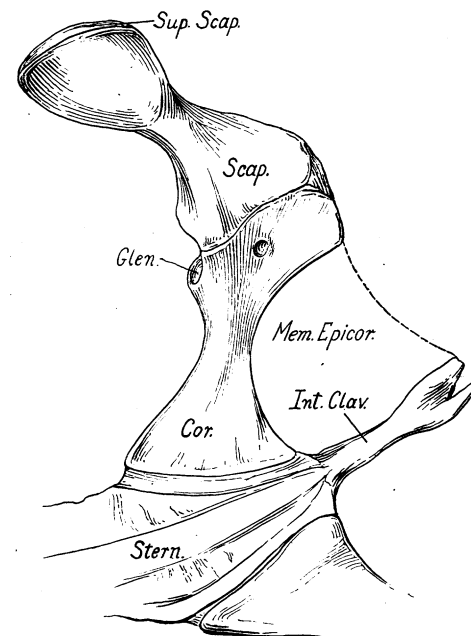
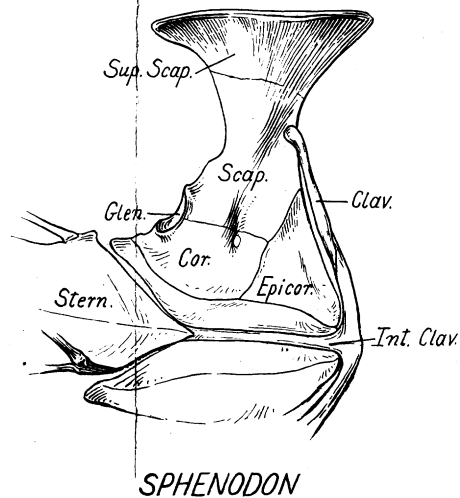
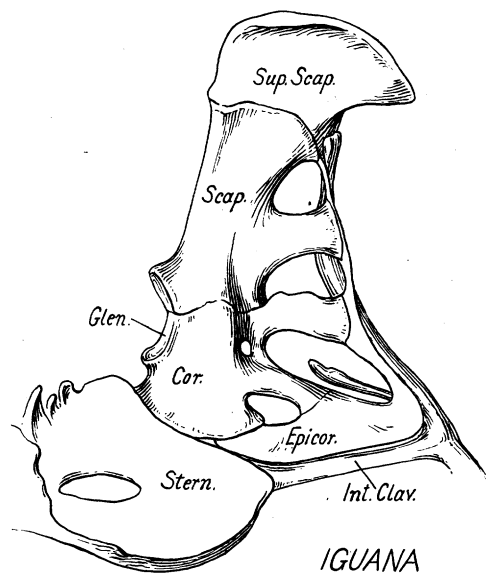
The most ancient and primitive type is in the center (*Dimetrodon gigas*). This has a deep trochanteric fossa and a high internal trochanteric, or adductor, crest, which probably served for the attachment of the ischiofemoralis (adductors), pubi-ischiofemoralis externus (obturator externus) and pubi-ischiofemoralis internus (iliopsoas + pectineus). At the left of the primitive type is the Therapsid-Mammal series, culminating in the marsupial (*Myrmecobius*) and primitive placental (*Pachyaena*) types, in which the internal trochanteric crest gives rise to the lesser trochanter (for the iliopsoas + pectineus). On the right of *Dimetrodon* is a morphological series leading toward the dinosaurs and showing the derivation of the fourth trochanter (for the insertion of the ischiofemoralis and caudifemoralis) from the internal trochanteric crest.



Ventral view of the coracoid region of (A) *Sphenodon*, (B) *Ornithorhynchus*, (C) *Homo*, showing the location of the principal muscle areas.

In all three cases the true coracoids serve for the origin of the coracobrachialis medius, the c. b. longus and the biceps muscles, while from the epicoracoids of *Sphenodon* and *Ornithorhynchus* arise the subcoraco-humeralis (= coracobrachialis brevis) and the supracoracoideus muscles. The "subcoracoid" centre of mammals is probably a new structure associated with the intracapsular origin of the long head of the biceps.

The supraspinatus muscle of mammals may have been derived either from the scapulohumeralis anterior or from the supracoracoideus of primitive reptiles.



Inner surface of the left half of the pectoral girdle of *Iguana*, *Sphenodon*, *Alligator*, *Echidna*, *Moschops* and *Ornithorhynchus*.

The most primitive conditions in the series are seen in the Permian reptile *Moschops*, which retains all the original elements including the cleithrum and the metacoracoid. The presence of a membranous epicoracoid is indicated by the form and relations of the coracoid in the mounted specimen. *Sphenodon* has lost the cleithrum and the metacoracoid but is otherwise primitive. In *Iguana* secondary vacuities are developed in the coracoid and scapula. In *Alligator* the single coracoid, still pierced by the supracoracoid foramen, is extended transversely; the clavicle is lacking but the epicoracoid is probably represented by the membrana episternocoracoideus. In *Echidna* and *Ornithorhynchus* the metacoracoid is lost and the epicoracoid, perhaps in adaptation to fossorial habits, becomes thick and well ossified. The coracoid is not perforated by the supracoracoid nerve, which passes through the large secondary opening above the epicoracoid. A vestigial ossicle (X) in a certain immature specimen of *Echidna* has somewhat the position of the metacoracoid but is of very doubtful homology.

